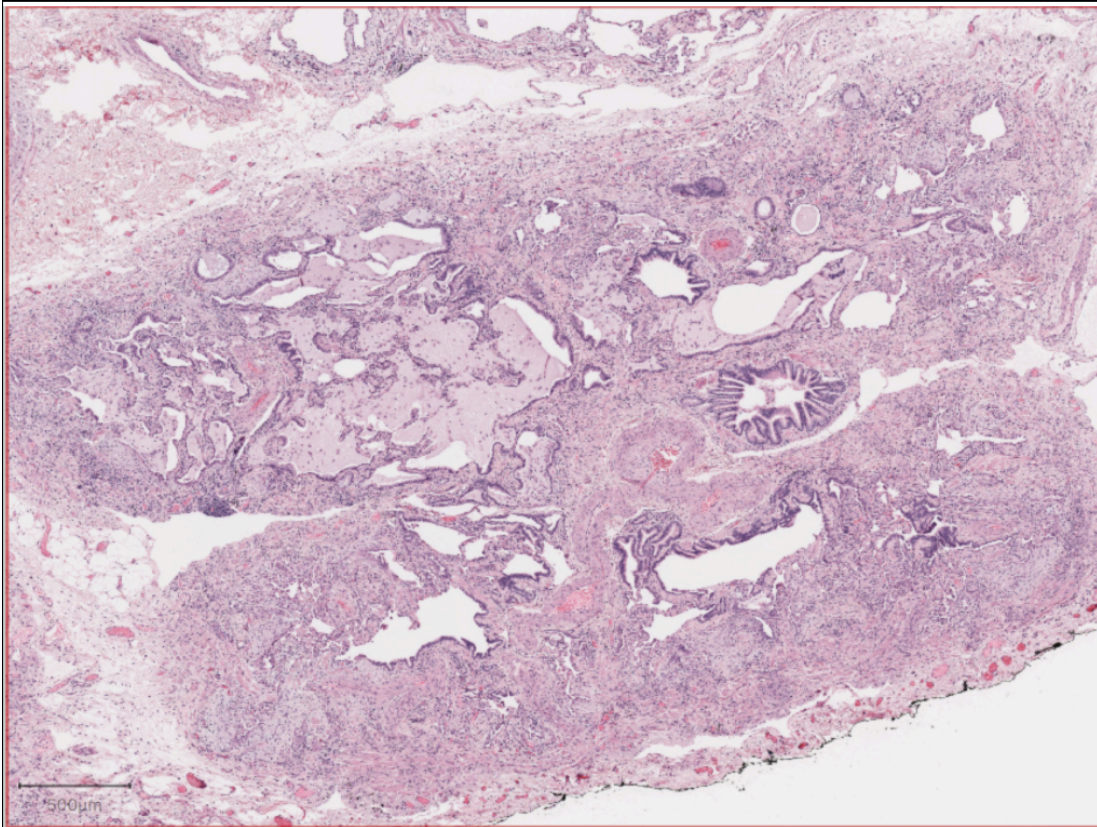




Fibrosis:

1 2 3 4 5 6 7 8 9 10 11 12 13 14 15 16 17 18 19 20 21 22



Queries:

Please evaluate the severity and pattern of fibrosis

Severe Fibrosis **i**

Yes No Uncertain

Pattern of Fibrosis **i**

Patchy Diffuse

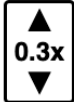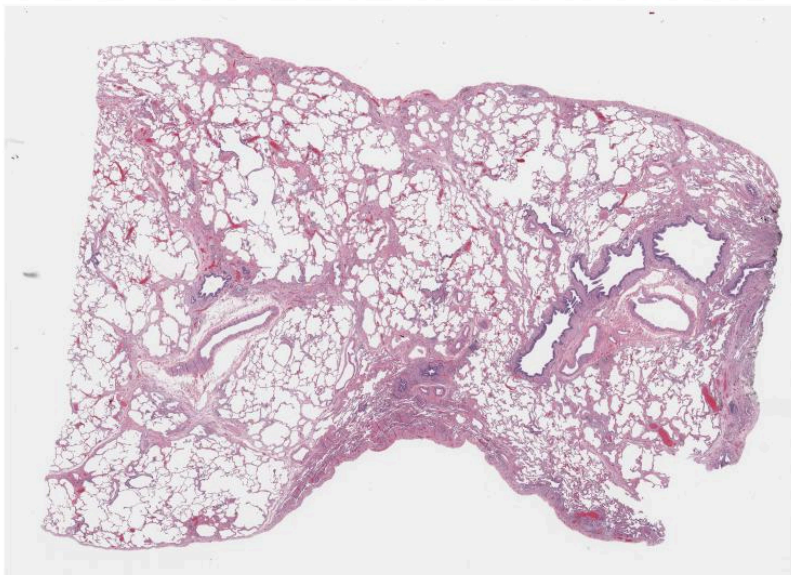
Honeycombing Only

Distribution

Subpleural/Paraseptal

Airway Centered Uncertain/Mixed

Supplemental figure 1



Queries:

Severe Fibrosis **i**
 Yes No

Pattern of Fibrosis **i**
 Patchy Diffuse
 Honeycombing Only

Distribution **i**
 Subpleural/Paraseptal
 Airway Centered Uncertain/Mixed

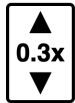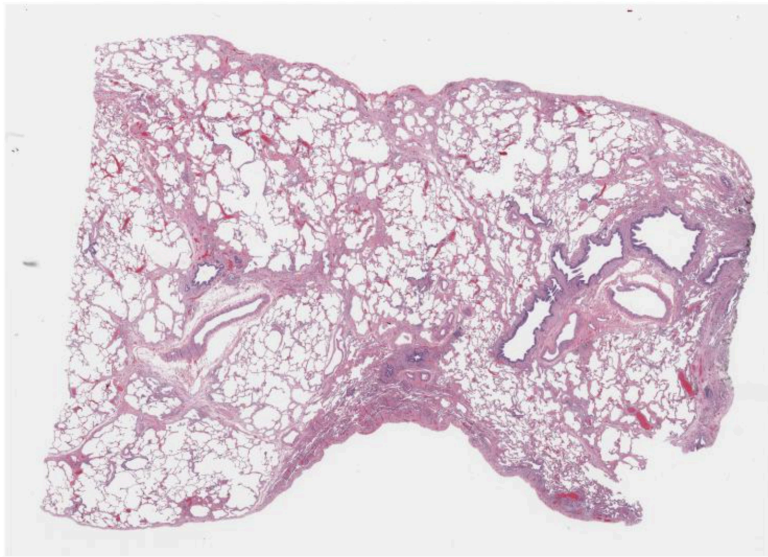
Fibroblast foci adjacent to dense scar **i**
 Readily Identified Rare
 None Cannot Determine

Specific Non UIP features **i**
 Dense Inflammation Away From Scar
 Granuloma Organizing Pneumonia
 Smoking-Related Interstitial Fibrosis
 Other (Comment Below)

Is this UIP/PF **i**
 Definite Probable Possible
 Not UIP/PF

Comments **i**

Supplemental figure 2a



Queries:

Severe Fibrosis **i**

No Yes Honeycombing Only

Distribution **i**

Subpleural/Paraseptal Irregular

Airway Centered Diffuse

Uncertain

Fibroblast foci adjcent to dense scar **i**

Readily Identified Rare None

Cannot Determine

Specific Non UIP features **i**

Excess Inflammation Granuloma

Organizing Pneumonia

Smoking-Related Interstitial Fibrosis

Other (Comment Below)

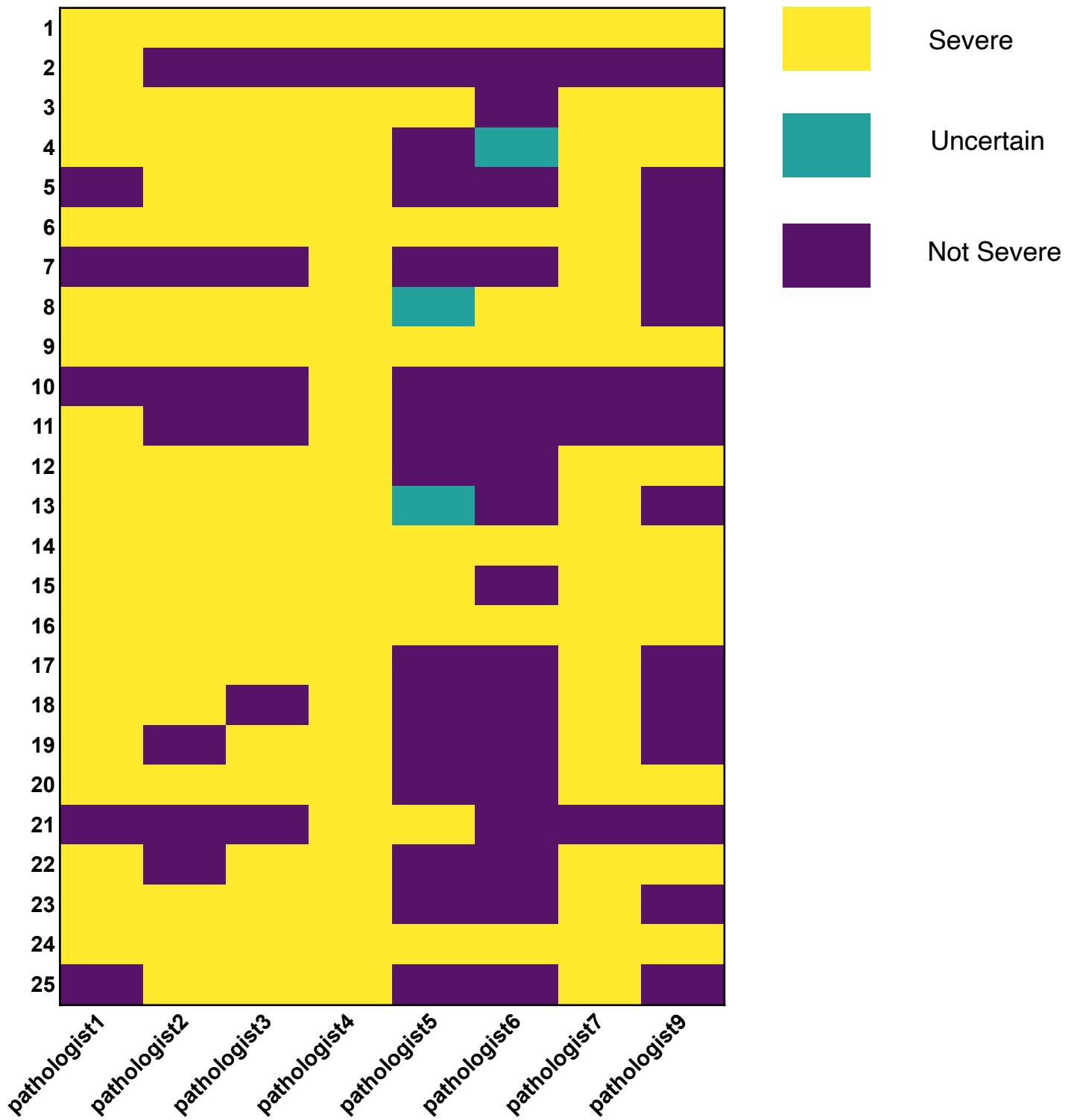
Is this UIP/PF **i**

Definite Probable Possible

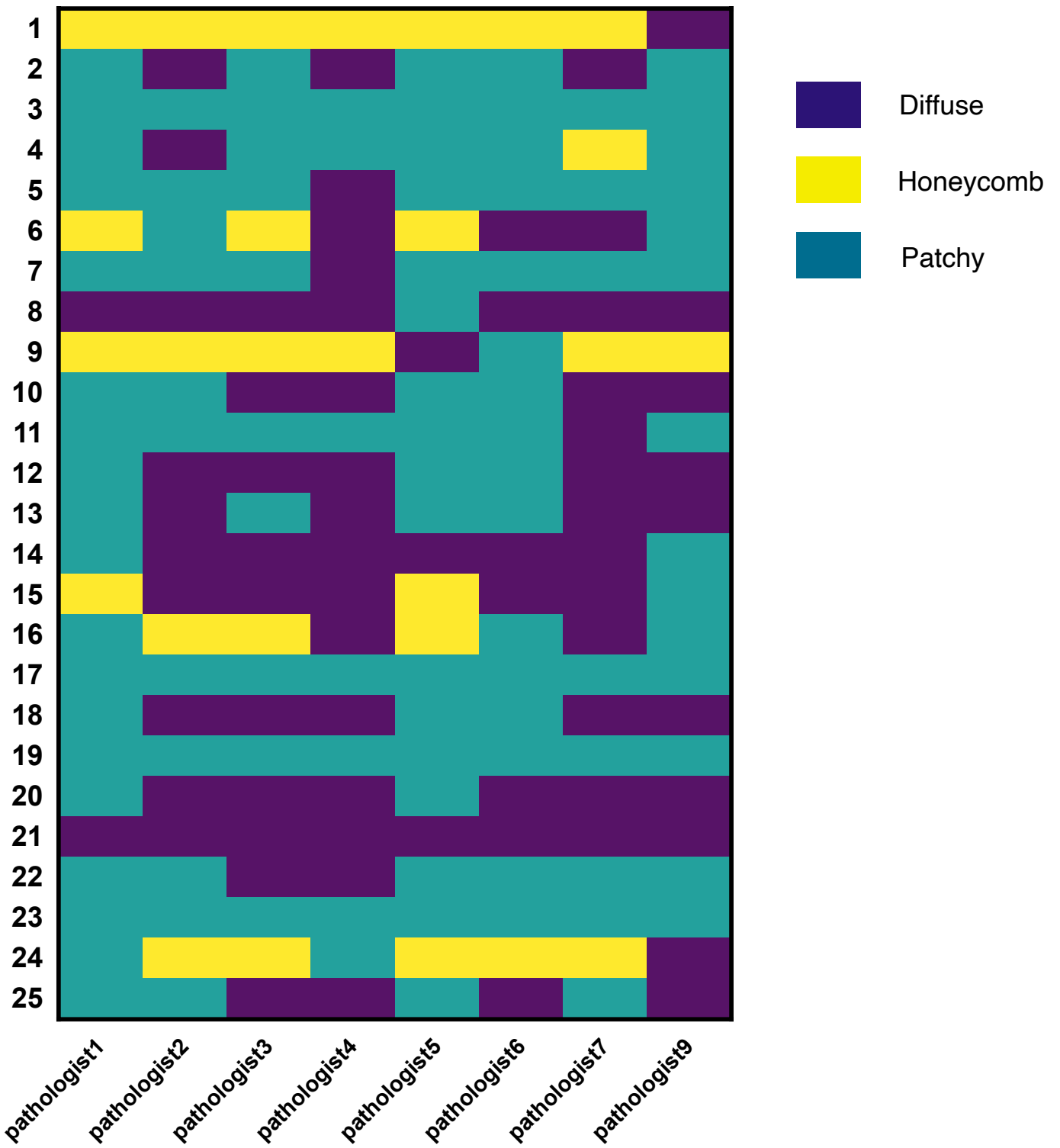
Not UIP/PF

Comments **i**

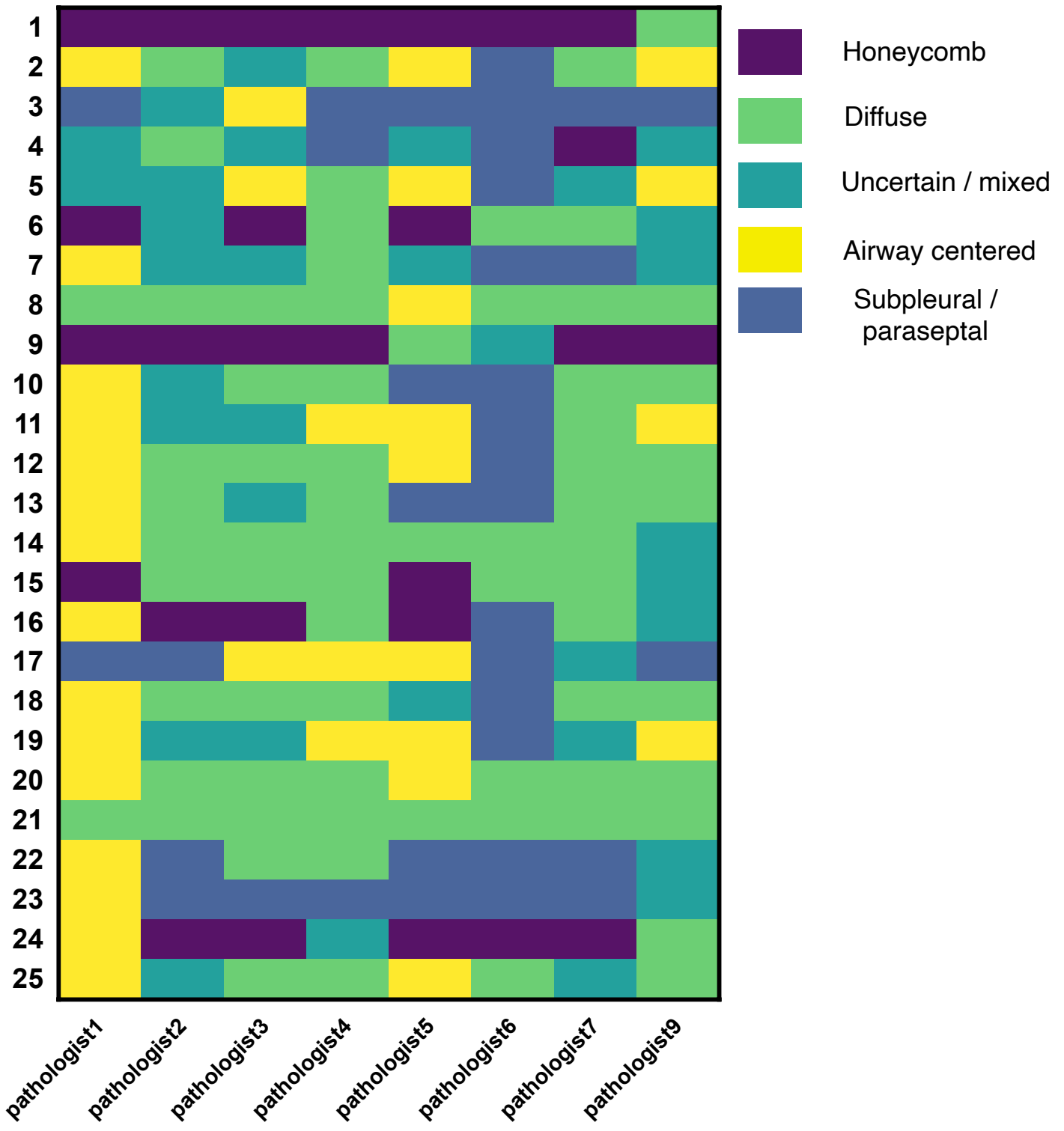
Supplemental figure 2b



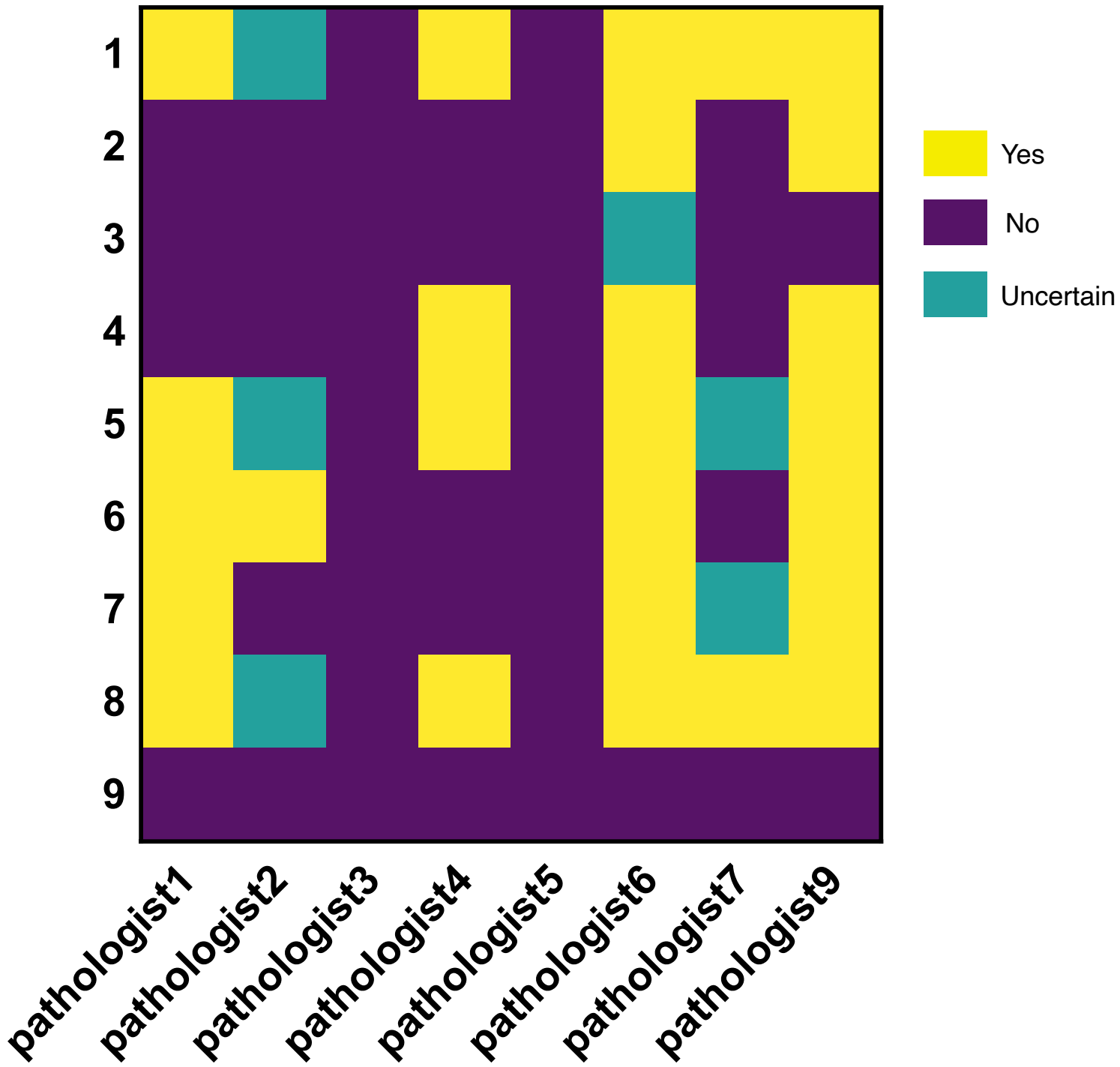
Supplemental figure 3a



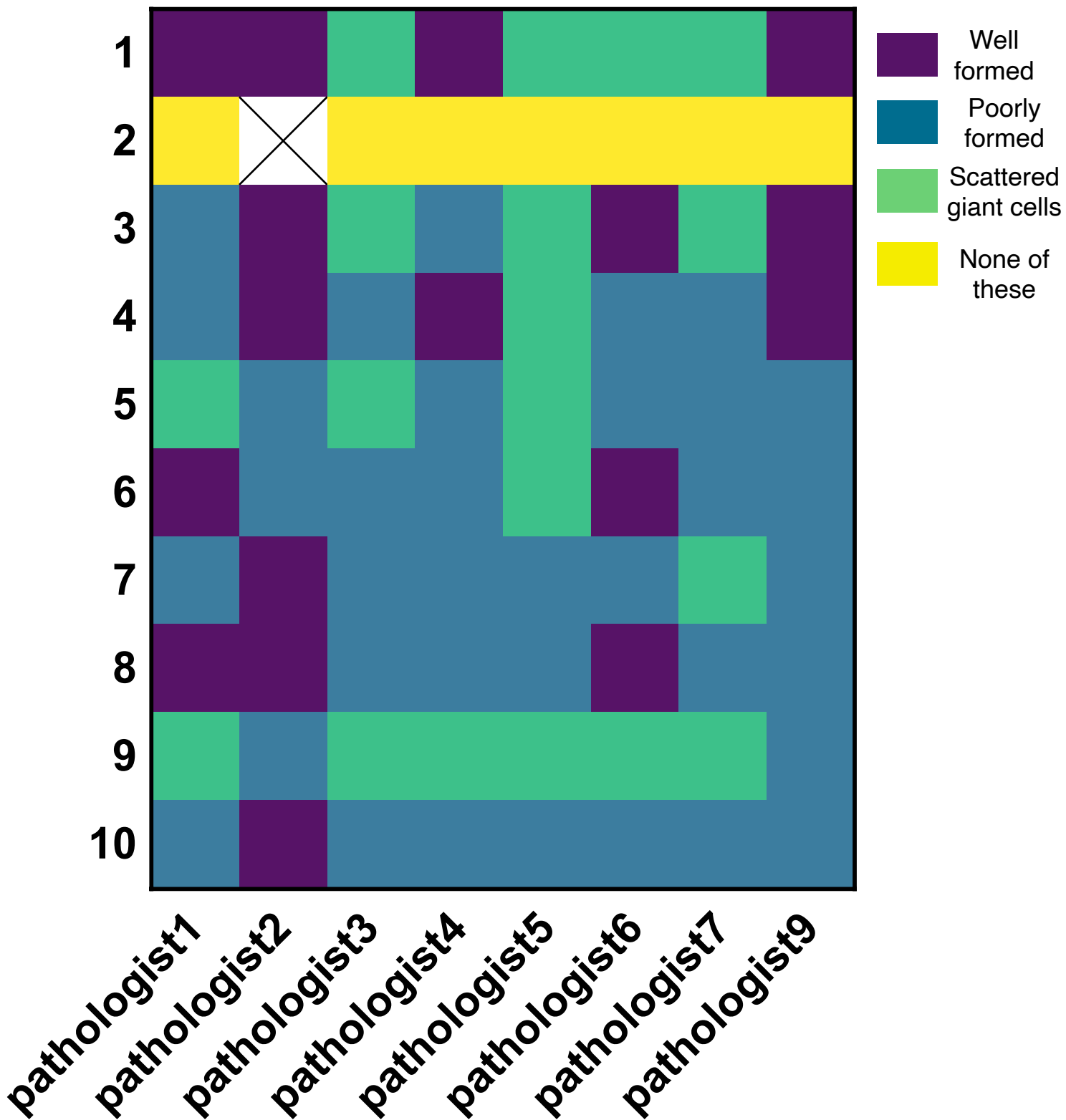
Supplemental figure 3b



Supplemental figure 3c



Supplemental figure 4



Supplemental figure 5