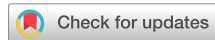

Transjugular Kidney Biopsy as a Safe Method to Increase the Etiological Diagnosis in Kidney Disease



Mónica Bolufer Cardona¹, Maria José Soler Romeo¹ and Gearoid M. McMahon²

¹Hospital Universitari Vall d'Hebron, Division of Nephrology Autonomous University of Barcelona, Barcelona, Spain; and ²Renal Division, Department of Medicine, Brigham and Women's Hospital, Harvard Medical School, Boston, Massachusetts, USA

Kidney Int Rep (2021) **6**, 2535–2536; <https://doi.org/10.1016/j.ekir.2021.08.007>

Copyright © 2021, International Society of Nephrology. Published by Elsevier Inc. This is an open access article under the CC BY-NC-ND license (<http://creativecommons.org/licenses/by-nc-nd/4.0/>).

See Clinical Research on Page 2594

Renal biopsy is an essential procedure for studying patients with kidney disease, being of great importance in the diagnosis and treatment, and to determine the prognosis of a patient.¹ The percutaneous, ultrasound-guided kidney biopsy is the most common technique used to obtain kidney tissue, but this is associated with a relatively high risk of complications. A recent systematic review and meta-analysis of 118,064 native kidney biopsies found that biopsy was associated with a number of complications, including pain at the puncture site (4.3%), hematomas (11%), gross hematuria (3.5%), need for transfusion (1.6%), intervention to stop bleeding (0.3%), and death (0.06%).² Overall, this study demonstrated that percutaneous

native kidney biopsy performed for diagnostic and prognostic purposes is normally safe; however, complication rates were higher in acute kidney disease and hospitalized patients.

The indications for transjugular renal biopsy (TJRB) have not been clearly defined, and it is usually used in specific clinical situations, such as morbid obesity, double organ biopsy, solitary kidney, or high bleeding risk (anticoagulants, cirrhosis, thrombocytopenia) (Figure 1). Strategies for the identification of patients who will benefit from TJRB are of great interest. A recent paper by Bolufer *et al.*¹ found that TJRB is safe and allowed for a histological diagnosis in two-thirds of patients for whom percutaneous ultrasound renal biopsy was contraindicated. Overall, despite the perceived elevated risk in this patient population, the published literature suggests that TJRB is in fact safe, with a good diagnostic performance and few major complications.^{3,4} A review of 17 retrospective articles published on 1321 TJRBs found that a

diagnosis was made in 90.3% of biopsies with major bleeding complications in 4.5%. Surprisingly, smaller biopsy needle size was not associated with a lower rate of complications.³ Another study by Cluzel *et al.*⁴ compared 400 transjugular with 400 percutaneous biopsies, concluding that with both techniques, tissue cores were adequate for histopathologic diagnosis and the complications were similar.

Halimi *et al.*⁶ studied a larger cohort of patients who underwent TJRB ($n = 5305$) from France. When they compared their TJRB with 55,026 patients who received percutaneous kidney biopsy, they demonstrated that TJRB was associated with lower risk of major bleeding, especially in patients at high risk, as defined by “major bleeding risk score” developed by the same group from prior work that includes parameters such as the Charlson comorbidity index, frailty index, anemia, thrombocytopenia, cancer, abnormal kidney function, acute kidney failure, glomerular disease, vasculitis, and thrombotic microangiopathy.⁶

In the current paper, Halimi *et al.*⁶ divided the patients according to the major bleeding risk score and studied the bleeding risk in the different groups. They found that in low-risk patients, the risk of bleeding was similar for transjugular versus percutaneous biopsy (0.4% and 0.5%), whereas high-risk patients had lower risk of bleeding if a transjugular biopsy was performed (19.1% vs. 30.8%). In the multivariate analysis, transjugular biopsy was associated with a lower risk of bleeding. Similarly, the presence of major bleeding was associated with a higher risk of death in both transjugular and

Correspondence: Mónica Bolufer Cardona, Division of Nephrology, Hospital Universitari Vall d'Hebron, Barcelona, Spain. E-mail: bolufermonica@gmail.com; or Maria José Soler, Hospital Universitari Vall d'Hebron, Division of Nephrology Autonomous University of Barcelona, Barcelona, Spain. E-mail: m.soler@vhebron.net

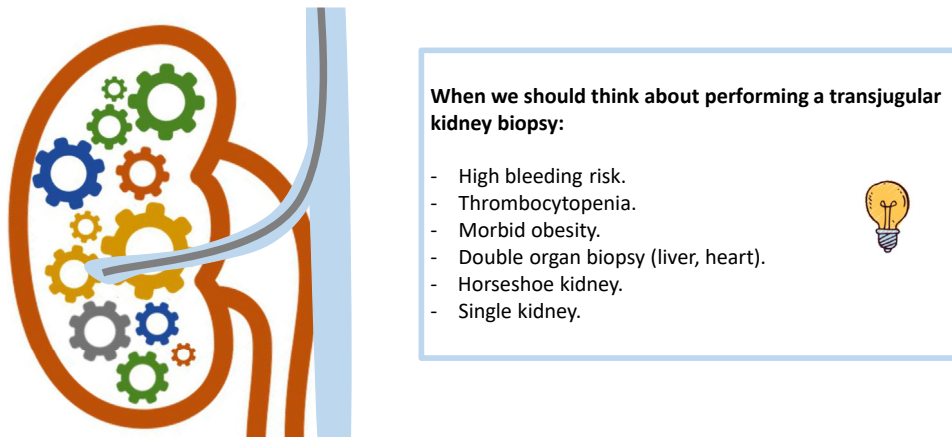


Figure 1. When we should think about performing a transjugular kidney biopsy.

percutaneous biopsy. This large retrospective study thus reinforces the idea that TJRB is indicated in a patient with high risk of bleeding, in whom the benefit seems clearer.^{1,6} However, it is important to note that the rate of TJRB appears to be higher in certain French institutions (included in this study) than elsewhere, and familiarity with the technique may play an important role in decreasing the rate of complications seen.

There are a number of important limitations of this study that may bias the results and reduce its generalizability. First, because the data were obtained from a national registry, diagnoses were based on International Classification of Diseases, 10th Revision codes rather than chart review. This could potentially overestimate the rate of bleeding associated with biopsies, as all patients who had a transfusion within a defined period following the biopsy were reported as having had a complication. This is supported by the fact that the rate of transfusion was higher than in the recent published literature, even in the lower-risk groups. Similarly, the rate of hematoma was substantially lower than would be expected, suggesting that some complications were not accurately recorded.

Second, one of the most important components of the risk score was the presence of anemia at the time of the biopsy. However, recent studies have shown that the magnitude of change in hemoglobin following a biopsy is not greater in patients with anemia at baseline and that, in fact, the higher rate of transfusion is solely because the prebiopsy hemoglobin is lower,⁵ reinforcing the knowledge that anemia alone should not be considered a significant risk factor for a hemorrhagic complication post percutaneous renal biopsy.⁶

Overall, despite these limitations, this is an important addition to the literature. Using a large cohort of patients undergoing both percutaneous and TJRB, Halimi *et al.*⁶ showed that TJRB is as safe as the percutaneous route, while generally providing enough tissue for diagnosis. They also found that the transjugular route is safer for certain high-risk patients. Taken together, this suggests that we can safely use this technique in patient populations for whom a percutaneous biopsy is relatively contraindicated. Future research should focus on identifying patients who would benefit most from this technique and developing algorithms to aid clinicians in deciding which route to pursue in higher-risk individuals.

DISCLOSURE

GM is a consultant for GlaxoSmithKline. MJS reports personal fees from NovoNordisk, Janssen, AstraZeneca, Fresenius, Mundipharma, Pfizer, Bayer, Vifor, Esteve, and Eli Lilly, and grants and nonfinancial support from Boehringer, outside the submitted work. MB declared no competing interests.

REFERENCES

1. Bolufer M, García-Carro C, Agraz I, et al. Biopsia renal transyugular. La alternativa a la biopsia percutánea en pacientes de alto riesgo. *Nefrología*. 2020 Jul;S0211699520300801.
2. Poggio ED, McClelland RL, Blank KN, et al. Systematic review and meta-analysis of native kidney biopsy complications. *Clin J Am Soc Nephrol*. 2020;15:1595–1602.
3. St. Jeor JD, Reisenauer CJ, Andrews JC, et al. Transjugular renal biopsy bleeding risk and diagnostic yield: a systematic review. *J Vasc Interv Radiol*. 2020;31:2106–2112.
4. Cluzel P, Martinez F, Bellin MF, et al. Transjugular versus percutaneous renal biopsy for the diagnosis of parenchymal disease: comparison of sampling effectiveness and complications. *Radiology*. 2000;215:689–693.
5. Whittier WL, Sayeed K, Korbet SM. Clinical factors influencing the decision to transfuse after percutaneous native kidney biopsy. *Clin Kidney J*. 2016;9:102–107.
6. Halimi JM, Gatault P, Longuet H, et al. Major bleeding of transjugular active kidney biopsies. *Kidney Int Rep*. 2021;6:2594–2603.