



TECHNICAL NOTE

Three-dimensional modelling as a novel interactive tool for preoperative planning for complex perianal fistulas in Crohn's disease

Sebastián Jeri-McFarlane¹ | Álvaro García-Granero^{1,2} | Aina Ochogavía-Seguí¹ | Gianluca Pellino^{3,4} | Anaí Oseira-Reigosa¹ | Alejandro Gil-Catalan¹ | Leandro Brogi⁵ | Daniel Ginard-Vicens⁶ | Margarita Gamundi-Cuesta¹ | Francisco Xavier Gonzalez-Argente¹

¹Colorectal Unit, General and Digestive Surgery Department, Hospital Universitario Son Espases, Palma de Mallorca, Spain

²Human Embryology and Anatomy Department, University of Islas Baleares, Mallorca, Spain

³Colorectal Surgery Unit, Vall d'Hebron University Hospital, Universitat Autònoma de Barcelona UAB, Barcelona, Spain

⁴Department of Advanced Medical and Surgical Sciences, Università degli Studi della Campania Luigi Vanvitelli, Naples, Italy

⁵Simulation and 3D Reconstruction Area, Hospital Universitario Son Espases, Palma de Mallorca, Spain

⁶Gastroenterology Department, Hospital Universitario Son Espases, Palma de Mallorca, Spain

Correspondence

Gianluca Pellino, Vall d'Hebron University Hospital, Universitat Autònoma de Barcelona UAB, Barcelona, Spain; Department of Advanced Medical and Surgical Sciences, Università degli Studi della Campania Luigi Vanvitelli, Naples, Italy.

Email: gianluca.pellino@uab.cat; gipe1984@gmail.com

Álvaro García-Granero, Colorectal Unit, General and Digestive Surgery Department, Hospital Universitario Son Espases, Palma de Mallorca, Spain. Email: alvarogggf@hotmail.com

Abstract

Aim: The aim of this study is to demonstrate the added value of three-dimensional (3D) reconstruction models and artificial intelligence for preoperative planning in complex perianal Crohn's disease. MRI is the gold standard for diagnosis of complex perianal fistulas and abscess due to its high sensitivity, but it lacks high specificity values. This creates the need for better diagnostic models such as 3D image processing and reconstruction (3D-IPR) with artificial intelligence (AI) algorithms.

Method: This is a prospective study evaluating the utility of 3D reconstruction models from MRI in four patients with perineal Crohn's disease (pCD).

Results: Four pCD patients had 3D reconstruction models made from pelvic MRI. This provided a more visual representation of perianal disease and made possible location of the internal fistula orifice, seton placement in fistula tracts and abscess drainage.

Conclusion: Three-dimensional reconstruction in CD-associated complex perianal fistulas can facilitate disease interpretation, anatomy and surgical strategy, potentially improving preoperative planning as well as intraoperative assistance. This could probably result in better surgical outcomes to control perianal sepsis and reduce the number of surgical procedures required in these patients.

KEYWORDS

artificial intelligence, Crohn disease, rectal fistula, three-dimensional imaging

INTRODUCTION

Perianal Crohn's disease (pCD) can present as complex fistulas in almost 80% of cases with recurrence rates of 19%–57% in some series [1]. These patients require three-dimensional (3D) ultrasound or magnetic resonance imaging (MRI) to recognize fistula tracts and occult abscess [2]. Nevertheless, even though MRI is the gold standard for diagnosis of complex perianal fistulas and abscess due to its high sensitivity, it lacks high specificity values (69% in some series) [3, 4]. This creates the need for better diagnostic models such as 3D image processing and reconstruction (3D-IPR) with artificial intelligence (AI) algorithms. 3D-IPR models have demonstrated that they can be used as an important tool for the management of these complex cases as well as creating a more spatial and intuitive model for surgical strategy planning [5]. Therefore, they can provide useful information and adequate knowledge of the anatomical relationships of those anorectal fistulas with adjacent pelvic structures so suitable surgical management can be planned and performed [5, 6]. Moreover, physical representation of fistula tracts improves the surgeon's understanding as well as patients' thoughts about surgical strategy [7].

It is important to emphasize that the main objective in locating abscess and treating fistula tracts is to control perianal sepsis and offer Crohn's disease (CD) patients the possibility to initiate otherwise contraindicated biological treatment.

METHOD

This video-assisted study aims to describe an initial experience with 3D virtual modelling of patients' pelvic anatomy and its relationship with complex fistulas to provide a tool for surgical preoperative planning.

First, the AI algorithm was developed from three retrospective cases. This means that patients had a preoperative MRI and then surgery was performed. Then, a prospective study was performed to evaluate the utility of 3D-IPR obtained from MRI to guide surgical intervention. Postoperative MRI was performed to assess the resolution of abscess or fistulas as seen at 3D-IPR.

Three-dimensional IPR requires the use of MRI to construct a visual representation of the pelvis while AI uses an algorithm called a deep convolutional neural network to analyse and perform a diagnosis with visual imagery. Convolutional operation generates a 2D output, but using stacks of these algorithms/filters would generate a 3D output [8]. Moreover, 3D-IPR uses MRI preprocessing using 'bias field correction' algorithms and anisotropic diffusion filtering of images. The 3D surface was reconstructed by means of modified marching cube algorithms [9]. Each pelvic structure was assigned a specific colour; red was used for internal fistula orifices, light blue for fistula tracts and green for abscess. An online platform afforded quick access to the 3D model and its manipulation during surgical intervention.

In the four analysed cases the following variables were collected: if the internal fistula orifice(s) was or were located in the area

indicated by the 3D reconstruction, if seton placement in the main fistula tracts was possible and if abscesses were adequately drained. Postoperative MRI was performed to evaluate successful abscess drainage.

In these four cases the AI algorithm was successful, but findings need to be further validated in wider samples of patients.

COMPARISON WITH OTHER METHODS

Endoanal ultrasound (EAUS), 3D-EAUS and MRI are still the ideal tools for the diagnosis of perianal disease and locating fistula tracts in pCD patients.

In some studies, the sensitivity and specificity of MRI in detecting fistulas were 87% and 69%, respectively. The specificity of EAUS can be as low as 43% [10]. Conversely, EAUS is superior to MRI at detecting internal fistula orifices, but specificity values for both modalities are considered to be diagnostically poor [10, 11]. The accuracy rate of EAUS is 80%–89% for delimiting fistula tracts and 91% for detecting an internal fistula orifice [12]. Additionally, 3D-EAUS may be able to grade fistula complexity but MRI provides higher accuracy for evaluating secondary extensions [11].

Moreover, the accuracy of these imaging techniques does not guarantee a better surgical outcome. Some studies show conflicting results in the impact of preoperative EAUS and the outcome of perianal disease [10, 12].

This translates into patients requiring multiple surgical procedures to treat abscess and fistulas due to high relapse rates, increased hospital stays and delayed optimal medical treatment due to monoclonal antibody contraindication if the focus of perianal sepsis is not controlled.

The main possible advantage of using 3D-IPR in pCD patients is to reduce the number of surgical interventions necessary to control perianal sepsis and drain fistula tracts with setons to initiate adequate medical treatment. Furthermore, fewer surgical procedures may reduce the risk of anal sphincter damage and consequent anal incontinence. Another advantage is that 3D-IPR does not require additional MRI sequences, extra time during MRI or contrast to create the 3D reconstruction [7].

It is important to note that the software used to create 3D models during this research has the particularity that it uses mathematical AI algorithms to detect fistula tracts, perianal abscess and even recognize the internal fistula orifice. This is an advantage over other software packages that do not use this method and require manual confirmation [13]. Moreover, AI algorithms make it possible to detect anatomical structures that may sometimes be difficult to detect even by an expert radiologist. Given the required time to develop the 3D model, the use of the technology also depends on the possibility to delay surgery; however, under some circumstances it is possible to have the results within 1 day.

On the other hand, using 3D-IPR does not require dedicated training by radiologists as it is based on variables objectively obtained from a MRI scan.

The main disadvantages of this technique are its elevated costs, availability and time necessary to create the 3D model. Therefore, it is a tool that must be indicated in specific circumstances, such as those described above.

RESULTS

Case 1 was a 14-year-old male patient with no other comorbidities presenting for the first time with a CD perianal abscess. The patient received initial treatment with azathioprine, which was changed to infliximab after resolution of the abscess. MRI was performed to provide the basis for a 3D-IPR model.

Preoperative axial MRI showed a primary intersphincteric fistula with a subcutaneous secondary tract. The inter-sphincteric fistula became trans-sphincteric at the anterior perineal raphe and produced a hemi-horseshoe abscess that extended all the way to the levator ani muscle. On the coronal segments a left supra-levator fluid collection was found following an intersphincteric route. All this information was then translated into the 3D-IPR.

During surgical intervention, the 3D model platform was continuously reviewed with a laptop. First, secondary fistula tracts were found and curettage performed. Then the left intersphincteric fistula was located and a seton placed with the help of the 3D model. Moreover, as seen in the MRI and the 3D reconstruction, the intersphincteric route to the supra-elevator space was discovered as well as the anterior trans-sphincteric fistula described previously. A mushroom catheter (Petzer drain) was placed in the supra-levator

space to allow further cleansing. Finally, setons were placed through subcutaneous secondary fistula tracts.

Postoperative MRI showed the catheter in the supra-levator space up to the prostate gland with the hemi-horseshoe abscess resolved. The mushroom catheter was removed after third dose of infliximab. The patient did not present any relapse of the abscess at a 6 month follow-up (Figure 1, Video S1).

Case 2 was a 23-year-old woman with CD debut with ileal disease and receiving initial steroid treatment; she then progressed to steroid-dependent disease requiring adalimumab. The patient required four surgical procedures for perianal sepsis. After the most recent abscess drainage, MRI was performed to demonstrate a trans-sphincteric perianal fistula with a posterior internal opening leading to two different trans-sphincteric tracts. A 3D-IPR was made from the MRI, showing the internal fistula orifice near the puborectalis muscle with a main extrasphincteric tract and secondary fistula tract associated with two left perirectal abscesses, one of which was near the levator ani muscle.

The surgical procedure was planned after 3D-IPR. The abscess was drained, and a mushroom catheter left in the cavity. A seton was placed on the main extrasphincteric tract. The secondary fistula tract was identified and a seton was placed. Postoperative MRI showed the mushroom catheter in place as well as correctly drained abscess without any relapse (Figure 2, Video S2).

Case 3 was a 31-year-old woman with terminal ileum CD. Initial treatment was budesonide. The patient required three surgical procedures for perianal disease. MRI was performed which showed a complex trans-sphincteric fistula with a posterior origin with three

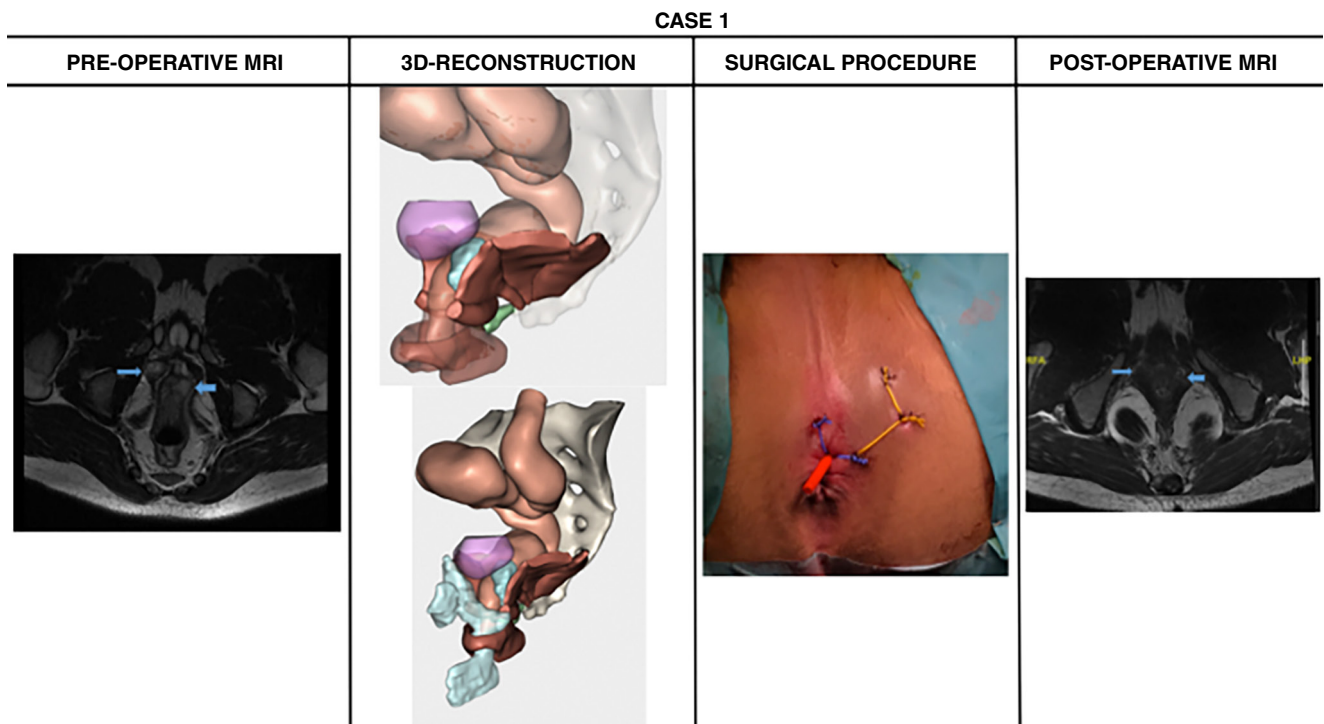


FIGURE 1 Summary of Case 1 (left to right): preoperative MRI, 3D-IPR, final view of surgical procedure, postoperative MRI. Arrows in preoperative MRI show abscess/fistula identification. Arrows in postoperative MRI show abscess resolution or drains in place.

CASE 2

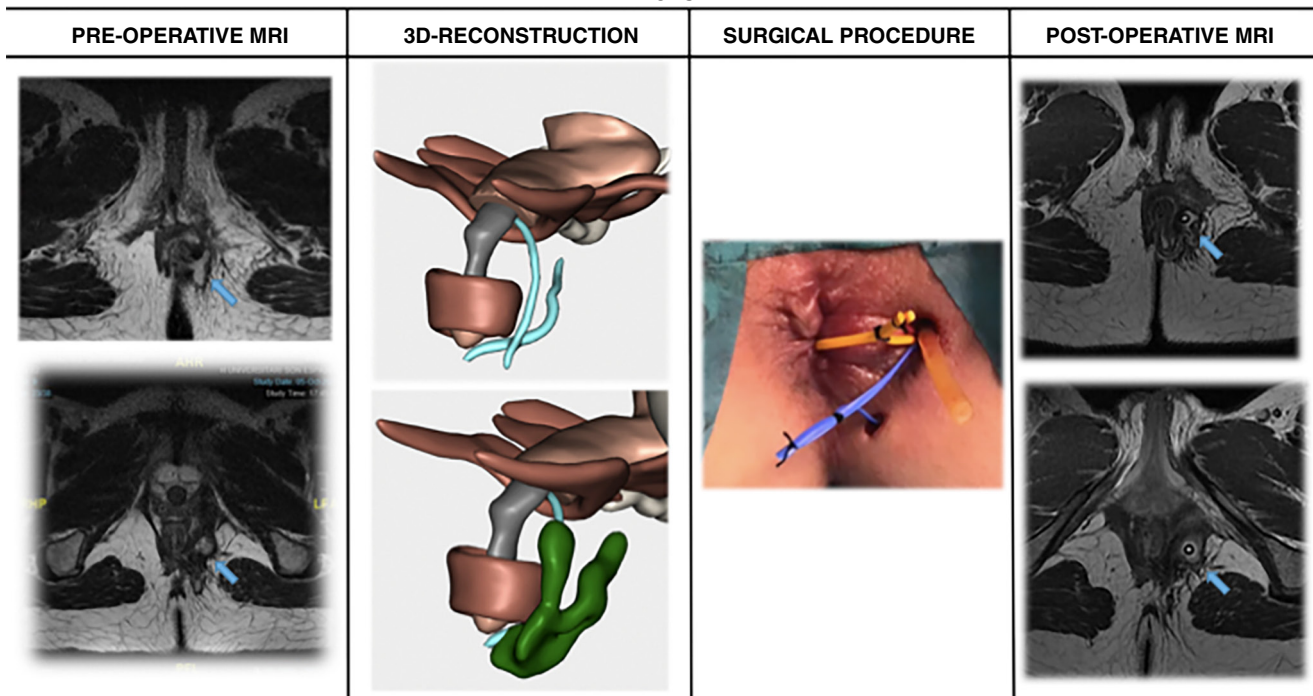


FIGURE 2 Summary of Case 2 (left to right): preoperative MRI, 3D-IPR, final view of surgical procedure, postoperative MRI. Arrows in preoperative MRI show abscess/fistula identification. Arrows in postoperative MRI show abscess resolution or drains in place.

CASE 3

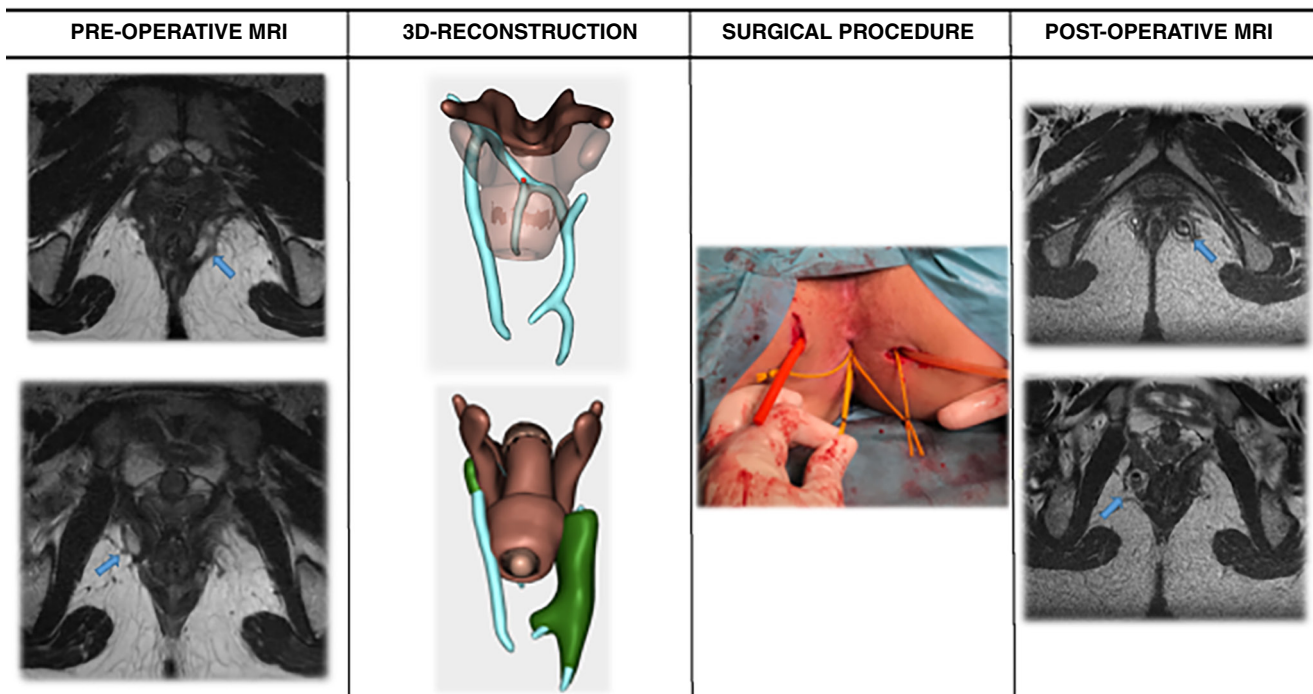


FIGURE 3 Summary of Case 3 (left to right): preoperative MRI, 3D-IPR, final view of surgical procedure, postoperative MRI. Arrows in preoperative MRI show abscess/fistula identification. Arrows in postoperative MRI show abscess resolution or drains in place.

different fistula tracts. 3D-IPR was performed from MRI, confirming a complex fistula with a common internal fistula orifice for the three fistulas located at the height of the puborectalis muscle. Additionally,

an abscess in the left fistulas was discovered and marked as well as a right ischioanal abscess near the levator ani muscle; neither were identified at initial MRI. The surgical procedure was performed after

CASE 4

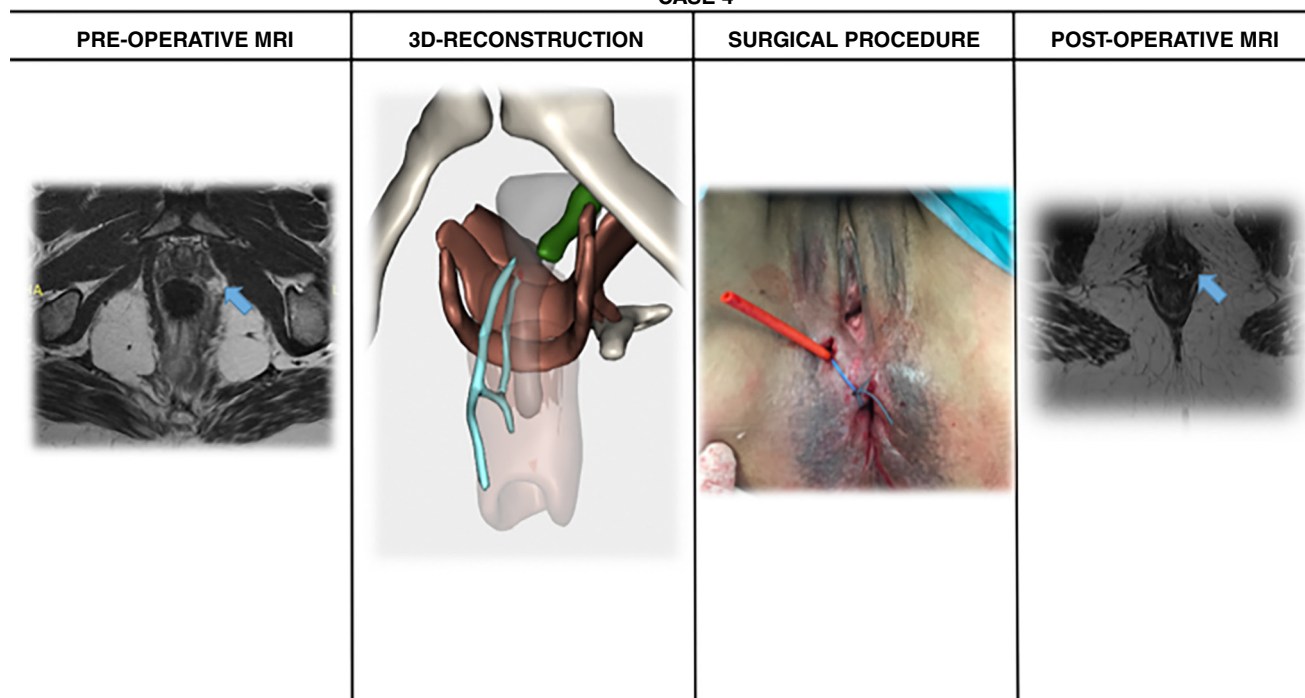


FIGURE 4 Summary of Case 4 (left to right): preoperative MRI, 3D-IPR, final view of surgical procedure, postoperative MRI. Arrows in preoperative MRI show abscess/fistula identification. Arrows in postoperative MRI show abscess resolution or drains in place.

TABLE 1 Summary of the four cases.

	Fistulas	Abscess	Seton placed on fistula tracts	Internal fistula orifice localized	Abscess drained ^a
Case 1	One inter-sphincteric, one trans-sphincteric, secondary subcutaneous	One hemi-horseshoe near to levator ani, one supra-levator	Yes	Yes	Yes
Case 2	T, One extra-sphincteric, one secondary subcutaneous	Two perirectal	Yes	Yes	Yes
Case 3	Three trans-sphincteric, common fistula orifice	One ischioanal, one left fistula	Yes	Yes	Yes
Case 4	Two trans-sphincteric	One levator ani	Yes	Yes	Yes

^aConfirmed with postoperative MRI.

3D-IPR, making it possible to place setons on the three fistula tracts via the common internal orifice; the mushroom catheter could be placed into the deep right ischioanal fossa. Postoperative MRI confirmed resolution of perianal sepsis and the placement of the catheter (Figure 3, Video S3).

Case number 4 was a 32-year-old woman with two previous perianal surgeries. MRI confirmed complex trans-sphincteric tracts with a deep internal fistula orifice forming an abscess near the levator ani muscle. 3D-IPR showed two complex trans-sphincteric tracts with the abscess marked in green. During surgery, a seton was placed along one of the trans-sphincteric tracts and on the second one curettage was performed, placing a mushroom catheter to the rectovaginal space. The surgical procedure solved the perianal sepsis, with postoperative MRI confirming this (Figure 4, Video S4).

CONCLUSIONS

Three-dimensional reconstruction of complex fistulas aids surgeons with an easier identification of secondary fistula, internal anal orifices or occult/deep abscess, which may otherwise be challenging to identify from MRI alone [5].

Three-dimensional model reconstruction does not offer additional information to that obtained with MRI, unless mathematical models are applied [9], but it improves conceptualization of complex fistulas as it provides a more realistic representation of the anatomy.

Three-dimensional reconstruction in CD with complex perianal fistulas might facilitate the interpretation of MRI by the surgeon, thus improving the surgical outcomes to allow complete drainage of septic fluid collections and location of possible internal fistula

orifices and fistula tracts to reduce the number of surgical procedures required to treat these patients (see [Table 1](#)).

FUNDING INFORMATION

None.

CONFLICT OF INTEREST STATEMENT

Dr García-Granero works for Cella Medical Solutions. He served as technical adviser for the current manuscript. All other authors have no conflict of interest to disclose.

AUTHOR CONTRIBUTIONS

SJMF Coinceived the article, collected and analysed data, and drafted the manuscript AGG coinceived the article, analysed data, and drafted the manuscript AOS collected and analysed data, and reviewed the article GP Coinceived the article and drafted the manuscript AOR collected and analysed data, and reviewed the article AGC collected and analysed data, and reviewed the article LB collected and analysed data, and reviewed the article DGV collected and analysed data, and reviewed the article MGC collected and analysed data, and reviewed the article FXGA analysed data, and reviewed the article for important intellectual content.

DATA AVAILABILITY STATEMENT

The data that supports the findings of this study are available in the supplementary material of this article.

ETHICAL APPROVAL

This study was conducted following the Declaration of Helsinki.

ORCID

Sebastián Jeri-McFarlane  <https://orcid.org/0000-0003-0319-2872>

Álvaro García-Granero  <https://orcid.org/0000-0003-1644-1241>

Aina Ochogavía-Seguí  <https://orcid.org/0000-0002-1874-7845>

Gianluca Pellino  <https://orcid.org/0000-0002-8322-6421>

Anaí Oseira-Reigosa  <https://orcid.org/0000-0002-2234-7705>

Alejandro Gil-Catalan  <https://orcid.org/0000-0001-8642-3925>

Francisco Xavier Gonzalez-Argente  <https://orcid.org/0000-0003-0003-9055>

<https://orcid.org/0000-0003-0003-9055>

TWITTER

Sebastián Jeri-McFarlane  @SebJeri21

Gianluca Pellino  @GianlucaPellino

Anaí Oseira-Reigosa  @AnaíOseira

Alejandro Gil-Catalan  @alejandrogilcat

REFERENCES

1. Torres J, Bonovas S, Doherty G, Kucharzik T, Gisbert JP, Raine T, et al. ECCO guidelines on therapeutics in Crohn's disease: medical treatment. *J Crohns Colitis*. 2019;2020:4–22.
2. Jeri-McFarlane S, García-Granero Á, Gil-Catalan A, Craus-Miguel A, Coll-Sastre M, Gamundi-Cuesta M, et al. Surgical strategy for supralevator abscess in Perianal Crohn's disease: emergency surgery and residual complex fistula. *Tech Coloproctology*. 2021;25(10):1163–4.
3. Lee JL, Yoon YS, Yu CS. Treatment strategy for perianal fistulas in Crohn disease patients: the surgeon's point of view. *Ann Coloproctol*. 2021;37(1):5–15.
4. Sudoł-Szopińska I, Santoro GA, Kołodziejczak M, Wiaczek A, Grossi U. Magnetic resonance imaging template to standardize reporting of anal fistulas. *Tech Coloproctol*. 2021;25(3):333–7.
5. Júnior ECS, Nogueira AT, Rocha BA, Filho WMNE, Meneses AD. Three-dimensional virtual reconstruction as a tool for preoperative planning in the management of complex anorectal fistulas. *J Coloproctology*. 2018;38(1):77–81.
6. Sahnan K, Adegbola SO, Tozer PJ, Burling D, Warusavitarne J, Faiz OD, et al. P126 experience of 3D modelling in perianal fistula disease and survey of international surgical interest. *J Crohns Colitis*. 2017;11(suppl_1):S140–1.
7. Sahnan K, Adegbola SO, Tozer PJ, Patel U, Ilangovan R, Warusavitarne J, et al. Innovation in the imaging of perianal fistula: a step towards personalised medicine. *Therap Adv Gastroenterol*. 2018;11:1756284818775060.
8. Hashimoto D, Meireles OR, Rosman G. Artificial intelligence in surgery: understanding the role of AI in surgical practice. McGraw-Hill Education; 2021.
9. Garcia-Granero A, Pellino G, Giner F, Frasson M, Fletcher-Sanfelici D, Romaguera VP, et al. A mathematical 3D-method applied to MRI to evaluate prostatic infiltration in advanced rectal cancer. *Tech Coloproctol*. 2020;24(6):605–7.
10. Siddiqui MRS, Ashrafian H, Tozer P, Daulatzai N, Burling D, Hart A, et al. A diagnostic accuracy meta-analysis of endoanal ultrasound and mri for perianal fistula assessment. *Dis Colon Rectum*. 2012;55(5):576–85.
11. Brilliantino A, Iacobellis F, Reginelli A, Monaco L, Sodano B, Tufano G, et al. Preoperative assessment of simple and complex anorectal fistulas: tridimensional endoanal ultrasound? Magnetic resonance? Both? *Radiol Med*. 2019;124(5):339–49.
12. Ding JH, Bi LX, Zhao K, Feng YY, Zhu J, Zhang B, et al. Impact of three-dimensional endoanal ultrasound on the outcome of anal fistula surgery: a prospective cohort study. *Colorectal Dis*. 2015;17(12):1104–12.
13. Day NJ, Earnshaw D, Salazar-Ferrer P, Walsh CJ. Preoperative mapping of fistula-in-ano: a new three-dimensional MRI-based modelling technique. *Colorectal Dis*. 2013;15(11):e699–701.

SUPPORTING INFORMATION

Additional supporting information can be found online in the Supporting Information section at the end of this article.

How to cite this article: Jeri-McFarlane S, García-Granero Á, Ochogavía-Seguí A, Pellino G, Oseira-Reigosa A, Gil-Catalan A, et al. Three-dimensional modelling as a novel interactive tool for preoperative planning for complex perianal fistulas in Crohn's disease. *Colorectal Dis*. 2023;25:1279–1284. <https://doi.org/10.1111/codi.16539>