



Research article

Correlation of the tumour-stroma ratio with diffusion weighted MRI in rectal cancer



Stéphanie M. Zunder^{a,f}, Raquel Perez-Lopez^b, Bente M. de Kok^c, Maria Vittoria Raciti^b, Gabi W. van Pelt^a, Rodrigo Dienstmann^d, Alonso Garcia-Ruiz^b, C. Arnaud Meijer^e, Hans Gelderblom^f, Rob. A. Tollenaar^a, Paolo Nuciforo^g, Martin N. Wasser^{c,1}, Wilma. E. Mesker^{a,1,*}

^a Department of Surgery, Leiden University Medical Centre, Albinusdreef 2, 2300 RC, Leiden, The Netherlands

^b Radiomics Group, Vall d'Hebron Institute of Oncology, Natzaret 115-117, 08035 Barcelona, Spain

^c Department of Radiology, Leiden University Medical Centre, Albinusdreef 2, 2300 RC Leiden, The Netherlands

^d Department of Oncology Data Science, Vall d'Hebron Institute of Oncology, Cellex Center, Natzaret 115-117 08035 Barcelona, Spain

^e Department of Radiology, Martini Hospital, Van Swietenplein 1, 9728 NT Groningen The Netherlands

^f Department of Medical Oncology, Leiden University Medical Centre, Albinusdreef 2, 2300 RC, Leiden, The Netherlands

^g Department of Molecular Oncology Group, Vall d'Hebron Institute of Oncology, Cellex Center, Natzaret 115-117 08035 Barcelona, Spain

ARTICLE INFO

Keywords:

Rectal neoplasms
Magnetic Resonance Imaging
Diffusion Magnetic Resonance Imaging
Tumor Microenvironment

ABSTRACT

Objective: This study evaluated the correlation between intratumoural stroma proportion, expressed as tumour-stroma ratio (TSR), and apparent diffusion coefficient (ADC) values in patients with rectal cancer.

Methods: This multicentre retrospective study included all consecutive patients with rectal cancer, diagnostically confirmed by biopsy and MRI. The training cohort (LUMC, Netherlands) included 33 patients and the validation cohort (VHIO, Spain) 69 patients. Two observers measured the mean and minimum ADCs based on single-slice and whole-volume segmentations. The TSR was determined on diagnostic haematoxylin & eosin stained slides of rectal tumour biopsies. The correlation between TSR and ADC was assessed by Spearman correlation (r_s).

Results: The ADC values between stroma-low and stroma-high tumours were not significantly different. Intraclass correlation (ICC) demonstrated a good level of agreement for the ADC measurements, ranging from 0.84–0.86 for single slice and 0.86–0.90 for the whole-volume protocol. No correlation was observed between the TSR and ADC values, with $ADC_{mean} r_s = -0.162$ ($p = 0.38$) and $ADC_{min} r_s = 0.041$ ($p = 0.82$) for the single-slice and $r_s = -0.108$ ($p = 0.55$) and $r_s = 0.019$ ($p = 0.92$) for the whole-volume measurements in the training cohort, respectively. Results from the validation cohort were consistent; $ADC_{mean} r_s = -0.022$ ($p = 0.86$) and $ADC_{min} r_s = 0.049$ ($p = 0.69$) for the single-slice and $r_s = -0.064$ ($p = 0.59$) and $r_s = -0.063$ ($p = 0.61$) for the whole-volume measurements.

Conclusions: Reproducibility of ADC values is good. Despite positive reports on the correlation between TSR and ADC values in other tumours, this could not be confirmed for rectal cancer.

1. Introduction

Colorectal cancer is the third most common cancer in Europe, with approximately 30% of these cancers arising from the rectum [1]. Current European guidelines on rectal cancer recommend performing a

pelvic magnetic resonance imaging (MRI) scan for locoregional staging, in order to predict the risk of synchronous and metachronous distant metastases, and to select the appropriate treatment [2]. MRI is thus the cornerstone of rectal cancer management. Hereby, advances are being made not solely in imaging quality, but also in attaining additional

Abbreviations: TSR, tumour-stroma ratio; H&E, haematoxylin and eosin; MRI, magnetic resonance imaging; ADC, apparent diffusion coefficient; DWI, diffusion weighted imaging; ROI, region of interest; SD, standard deviation; ICC, intraclass correlation coefficient.

* Corresponding Author at: Department of Surgery, Leiden University Medical Centre Albinusdreef 22333 ZA Leiden The Netherlands

E-mail address: w.e.mesker@lumc.nl (Wilma.E. Mesker).

¹ Shared last authors.

<https://doi.org/10.1016/j.ejrad.2020.109345>

Received 15 June 2020; Received in revised form 6 September 2020; Accepted 7 October 2020

Available online 13 October 2020

0720-048X/© 2020 The Author(s). Published by Elsevier B.V. This is an open access article under the CC BY license (<http://creativecommons.org/licenses/by/4.0/>).

information on tumour biology. Tumour masses are pathologically complex structures, which can consist of almost up to 50 percent of stroma cells, wherein cancer-associated fibroblasts, immune cells and angiogenic vascular cells create an activated tumour microenvironment, promoting tumour progression, angiogenesis, invasion and metastasis [3–5]. Microscopic quantification of the amount of intratumoural stroma, referred to as the tumour-stroma ratio (TSR), has proven to be prognostic in various solid tumours [6–13], wherein a high proportion of intratumoural stroma is associated with a poor prognosis.

Recently, several studies have been published on the correlation between intratumoural stroma and MR-imaging, whereby diffusion-weighted imaging (DWI) permits quantitative measurement of diffusion of water molecules, hence providing information on tumour cellularity [14,15]. This measurement is constructed from parametric apparent diffusion coefficient (ADC) maps and has proven to correlate with stroma proportion in breast-, oesophageal-, prostate- and head and neck squamous cell cancers [16–21]. In rectal cancer, studies have focussed on MRI-DWI parameters in relation to disease detection [22, 23], response to neoadjuvant therapy [24,25] and tumour aggressiveness [26].

To our knowledge, the value of quantitative ADC measurements as a surrogate of stroma infiltration has not been evaluated in rectal cancer. Therefore, the aim of this study is to evaluate whether there is a correlation between the intratumoural stroma proportion (i.e. TSR) and ADC values as derived from MRI-DWI, in order to determine if there is potential for this parameter as biomarker for clinical decision making with respect to neoadjuvant treatment and patient follow-up.

2. Material and Methods

2.1. Study population

For this study, we retrospectively assembled two cohorts of patients diagnosed with rectal cancer. First, a pilot study was performed with patients from LUMC (The Netherlands). In order to validate the findings of our *LUMC cohort*, an independent validation cohort was assembled in collaboration with Vall d'Hebron University Hospital in Barcelona (Spain). Noteworthy to mention, Vall d'Hebron University Hospital included DWI in the standard protocol for rectal cancer in 2011, whereas the LUMC started with incorporation in 2015, which influenced the sample size of the training and validation cohort.

2.2. The LUMC cohort

The local institutional ethics committee approved this study and considering the retrospective design no additional patient consent was needed.

All patients who had a histologically proven diagnosis of rectal cancer in our institution, between January 2015 – January 2017, were eligible for this study, provided that a diagnostic (pre-treatment) biopsy and diagnostic MRI scan with DWI sequences were available.

2.3. The VHIO cohort

For the validation cohort we included all patients undergoing standard care for a histologically proven stage 2 or 3 rectal carcinoma with an available MRI-scan with DWI, between January 2011 - January 2018, from the Vall d'Hebron University Hospital. The local institutional ethics committee approved this study, likewise to the *LUMC cohort* no additional patient consent was needed based on the retrospective study design.

2.4. Histopathological analysis

Available haematoxylin and eosin (H&E) stained tumour tissue slides of diagnostic rectal biopsies were scored for tumour-stroma ratio,

according to the method described by Mesker et al [8]. In summary, the area with the highest amount of stroma is selected using a 2.5x or 5x objective. Using a 10x objective, an area with tumour cells present at all borders is scored. Stroma percentages are given per tenfold (10%, 20% etc.) per image field. A previously determined cut-off is used to divide the scoring percentages into the categories stroma-high (> 50%) and stroma-low (\leq 50%) [8]. In case multiple sections were available per patient, all biopsies were scored for TSR. The highest score determined the final stroma classification. Scoring of the H&E stained slides from the *VHIO cohort* was performed digitally, using NanoZoomer Digital Pathology (NDP.view 2, Hamamatsu). First, the entire tissue slide was visually evaluated to determine the area with stroma abundance, subsequently the most stroma-rich area was marked with a circular annotation of 3.1 mm² and scored based on the previously described method. The chosen annotation size is based on the 10x objective used in microscopic scoring, which varies between 2.54 and 3.80 mm², depending on the oculars that are used (Fig. 1) [27].

The two investigators (SZ, GP) were blinded to the clinical characteristics and ADC values during histopathological scoring.

All pathological material was handled according to Dutch national ethical guidelines (i.e. "Code for Proper Secondary Use of Human Tissue", Dutch Federation of Medical Scientific Societies).

2.5. MRI protocol

In the *LUMC cohort*, MRI was performed on a 1.5-T or 3.0-T MRI device (respectively, Ingenia or Intera, Philips Healthcare, The Netherlands) using a phased array or 16 channel torso coil. MRI of the *VHIO* patients was performed on a 1.5-T MRI device (Avanto, Siemens Healthcare, The Netherlands). A dose of 20 mg of the spasmolytic agent hyoscine butylbromide (Buscopan, Boehringer Ingelheim) was administered intravenously to all patients immediately prior to MR imaging. The imaging protocol consisted of standard T2-weighted turbo spin-echo sequences in three orthogonal directions, slice thickness 3–4 mm, and axial DWI (single-shot spin echo-planar imaging) sequence with diffusion sensitivity values (b values) of 0, 200, and 800 sec/mm² in the *LUMC cohort* and 0, 500 and 1000sec/mm² for the vast majority of the *VHIO cohort* with slice thickness 5 mm. The DWI sequence was set and angulated identically to the axial T2-weighted turbo spin-echo sequence, perpendicular to the tumour axis. ADC maps were generated automatically and included all three b values in a monoexponential decay model.

2.6. Image analysis and ROI methods

All MRI images were retrieved from the PACS-system for further analysis. In case no ADC map was available, this was calculated using Philips IntelliSpace Portal 9.0 software.

Both centres applied an identical image analysis protocol. The *LUMC cohort* was scored by one radiologist (AM) and one senior resident specialized in abdominal imaging (BK) with respectively 6 and 4 years of experience, whereas the *VHIO cohort* was scored by a senior resident (MR) with 5 years of experience and a radiologist (RPL) with 10 years of experience. All radiologists reviewed the MR images independently and were blinded to each other's results as well as to the clinical patient characteristics, with exception to the diagnosis rectal cancer.

Tumour ADC measurements were obtained using two different protocols; (1) single-slice, (2) whole-volume. For the single-slice method, a single freehand ROI was drawn alongside the tumour border of the image-slice containing the largest tumour area. The tumour areas were considered as the focal masses showing high signal intensity compared with the signal of the normal adjacent rectal wall on the DWI high b values and corresponding to intermediate signal intensity on the anatomical T2-weighted images. For the whole-volume method, a total of up to five freehand ROIs were drawn along the tumour border of consecutive tumour containing slices according to the previously

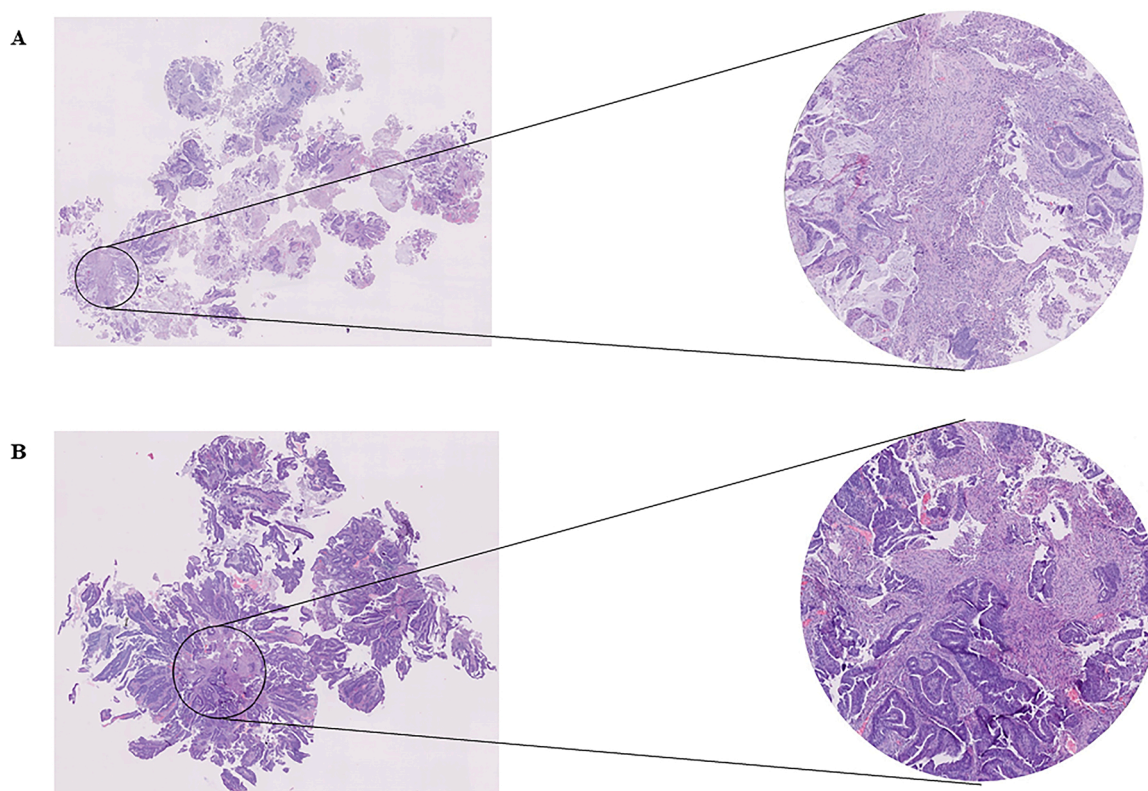


Fig. 1. Haematoxylin and eosin (H&E) stained paraffin sections of rectal cancer biopsies with 10x objective magnification for scoring.
1a. Stroma-high.
1b. Stroma-low.

described method [25,28]. Mean ADC and minimal ADC were determined for each slice (Fig. 2). For further analyses of whole-volume measurements, a final mean of these parameters was calculated per observer. For further analysis of ADCs, the results of both observers were averaged.

2.7. Statistical analysis

Inter-observer agreement for TSR scoring was tested using Cohen's kappa coefficient. Inter-observer agreement for single-slice and whole-volume (five measurements) ADC measurements was analysed by calculating the intraclass correlation coefficient (ICC) < 0.5 poor, 0.50 - 0.75 moderate, 0.75 - 0.90 good, > 0.90 excellent correlation).

Depending on the distribution, either the unpaired T-test or Mann-Whitney U-test was used to compare the mean ADC values between the two TSR categories.

Spearman's rank correlation (r_s) was used to determine the correlation between the TSR scores and ADC measurements.

Statistical analyses were performed using the Statistical Package for the Social Sciences (SPSS, version 23.0, Chicago, IL, USA) and R version 3.5.3. A p -value < 0.05 was considered to indicate statistical significance.

3. Results

3.1. Study population

Rectal biopsies were available from 52 patients, from which 44 (84.6%) were suitable for histopathological scoring. MRI-scans with adequate DWI images and ADC-maps were available in 41 (78.8%) patients. The resulting study population from whom both parameters were available consisted of 33 patients. This group contained 25 men (75.8%)

and 8 women (24.2%), with a median age of 70 years (range 46 - 81). Additional baseline characteristics are provided in Table 1.

A total of 100 H&E slides from 52 patients were evaluated for TSR. Twenty-three patients (44%) were classified as stroma-low, 21 patients (40%) as stroma-high and in 8 cases (16%) the score could not be determined due to lack of invasive tumour and/or low quality of the material.

As previously mentioned, adequate TSR and ADC parameters were available in 33 patients; 16 (48.5%) classified as stroma-low and 17 (51.5%) as stroma-high.

Material of 82 rectal cancer patients was available for histopathological scoring. Thirteen (15.8%) patients were excluded due to the absence of a diagnostic MRI, resulting in a validation cohort of 69 patients. This group contained 39 men (57%) and 30 women (43%), with a median age of 68 years (range 45 - 87). See Table 1 for patient characteristics.

Thirty-two patients (46.4%) were classified as having stroma-high tumours and 37 patients (53.6%) as stroma-low tumours.

3.2. Inter-observer agreement

Cohen's kappa coefficient showed a substantial to excellent level of agreement for TSR scoring, respectively $\kappa = 0.84$ for LUMC cohort and $\kappa = 0.67$ for VHIO cohort.

For the ADC measurements a good level of agreement was achieved. For single-slice measurements the ICCs ranged from 0.84 - 0.86, whereas for the whole-volume measurements from 0.86 - 0.90 (Table 2).

3.3. Correlation between tumour-stroma ratio and ADC values

For both the single-slice and whole-volume measurements, the mean

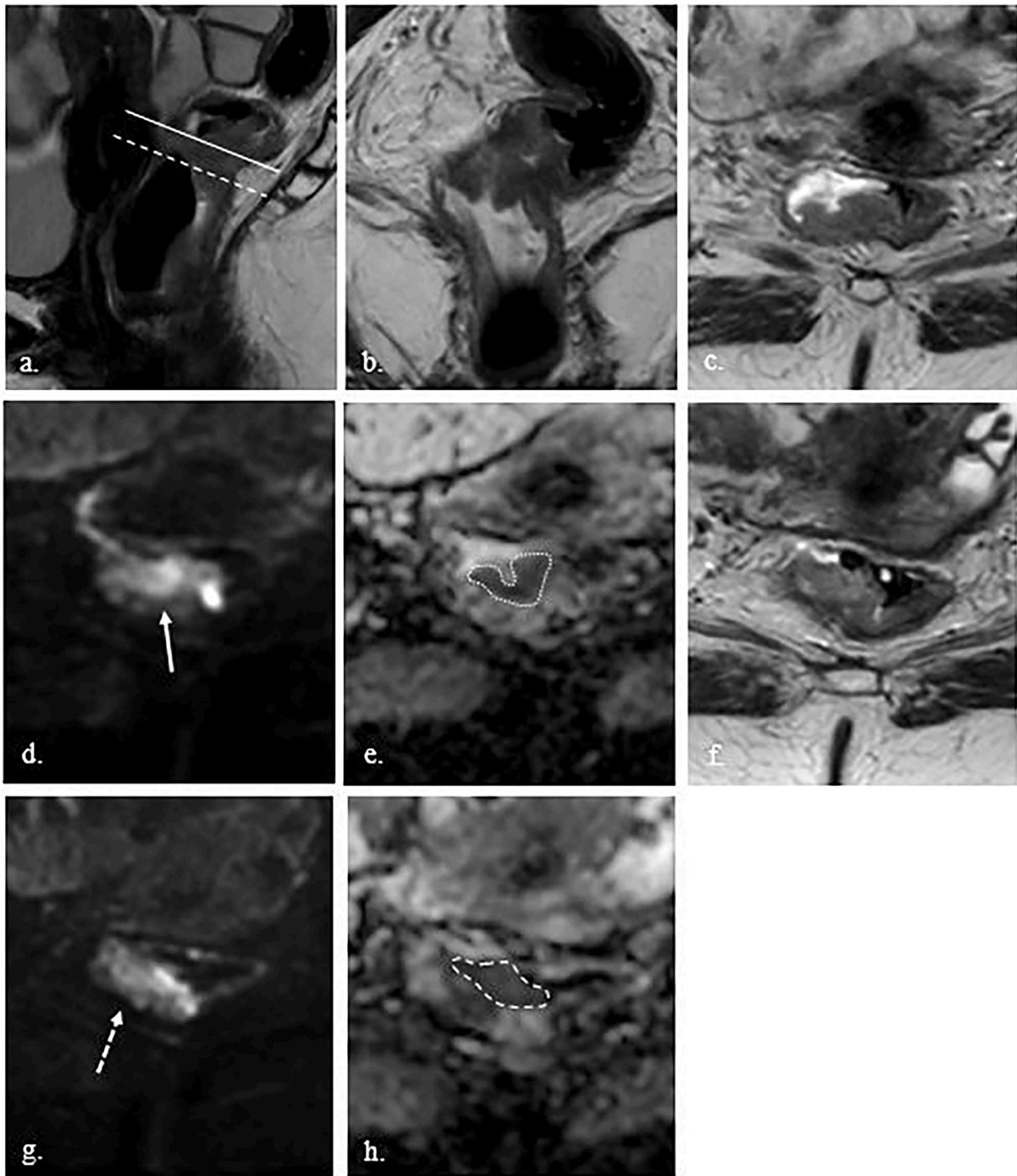


Fig. 2. MRI performed for primary tumour staging in a 65 year old female.

(a-b) Sagittal and coronal T2-weighted image showing a semi circumferential mass dorsally in the midrectum with a tumour length of approximately 3 cm.

(c) Axial T2-weighted image perpendicular to the tumour-axis at a caudal level (*striped line in Fig. 1a*), showing a mass on the dorsal rectal wall.

(d) Axial DW image with a b value of 800 sec/mm², derived at the same level as *Fig. 1c*, perpendicular to the tumour-axis. The image shows crescent-shaped diffusion restriction in the mass (*arrow*).

(e) ADC map at the same caudal level, showing corresponding crescent-shaped hypo-intense signal in the tumour, delineated by a manually drawn ROI (*dotted line*).

(f) Axial T2-weighted image perpendicular to the tumour-axis at a more cranial level (*solid line in Fig. 1a*).

(g-h) Axial DW image and ADC map at the same level as *Fig. 1f*, respectively a *striped line* pointing towards and a *striped ROI* delineating the tumour.

of ADC-values was not significantly different between stroma-low and stroma-high tumours, in both cohorts respectively (*Table 3; Fig. 3*).

For the *LUMC cohort* Spearman rank correlation analyses ruled out a significant correlation between the TSR and the various ADC measurements, with $ADC_{mean} r_s = -0.162$ ($p = 0.38$) and $ADC_{min} r_s = 0.041$ ($p = 0.82$) for the single-slice measurements and $r_s = -0.108$ ($p = 0.55$) and r_s

$= 0.019$ ($p = 0.92$) for the whole-volume measurements, respectively. The results from the validation cohort were consistent, with $ADC_{mean} r_s = -0.022$ ($p = 0.86$) and $ADC_{min} r_s = 0.049$ ($p = 0.69$) for the single-slice measurements and $r_s = -0.064$ ($p = 0.59$) and $r_s = -0.063$ ($p = 0.61$) for the whole-volume measurements.

Table 1
Baseline characteristics of LUMC training cohort and VHIO validation cohort

Baseline characteristics of LUMC training cohort and VHIO validation cohort								
	LUMC training cohort			P-value	VHIO validation cohort			P-value
	N=	Stroma-low	Stroma-high		N=	Stroma-low	Stroma-high	
Gender								
Female	8	3 (37%)	5 (63%)	0.48	30	14 (47%)	16 (53%)	0.34
Male	25	13 (52%)	12 (48%)		39	23 (59%)	16 (41%)	
Median age in years (range)	33	71.5 (53 – 78)	64.0 (46 – 81)	0.09		68.9 (49 – 87)	67.3 (45 – 84)	0.35
Mean tumor size (mm)	23	26.7 (15 – 41)	22.3 (8 – 39)		NA	NA	NA	
Histological grade								
undifferentiated	NA	NA	NA	0.68	NA	NA	NA	0.28
well differentiated	1	1 (100%)	0		20	8 (40%)	12 (60%)	
moderately differentiated	20	9 (45%)	11 (55%)		24	14 (58%)	10 (42%)	
poor differentiated	7	3 (43%)	4 (57%)		7	3 (43%)	4 (57%)	
unknown	5	3 (60%)	2 (40%)		17	12 (71%)	5 (29%)	
cTNM								
I	5	3 (60%)	2 (40%)	0.39	NA	NA	NA	0.43
II	4	3 (75%)	1 (25%)		11	8 (73%)	3 (27%)	
III	19	9 (47%)	10 (53%)		57	29 (51%)	28 (49%)	
IV	5	1 (20%)	4 (80%)		NA	NA	NA	

Abbreviations: NA not applicable

Table 2
Inter-observer agreement MRI analyses LUMC training cohort

Parameter	Level of agreement	
Tumour-stroma ratio	$\kappa = 0.84$	
ADC measurements	Single slice	Whole-volume
ADC _{mean}	ICC = 0.84	ICC = 0.86
ADC _{min}	ICC = 0.86	ICC = 0.90

Abbreviations: ADC Apparent diffusion coefficient, ICC intraclass correlation coefficient

4. Discussion

To our knowledge, this is the first study to correlate diffusion restriction on MRI as expressed by quantitative ADC measurements to the amount of tumour stroma in rectal cancer, to determine whether it holds potential as a biomarker for clinical decision making with respect to neoadjuvant treatment and patient follow-up. In our study we did not find a correlation between ADC values and the tumour-stroma ratio. This was unexpected, since numerous previous studies in other solid cancers clearly found a correlation between MRI parameters and TSR [17,18,29–31]. For instance, Ko et al. demonstrated a significantly lower ADC_{mean} in stroma-low tumours ($p < 0.001$) and a negative correlation

between TSR and the ADC_{mean} ($r_s = -0.545$; $p < 0.001$) in breast cancer patients [18]. Four other studies, performed in prostate- and breast cancer, could not demonstrate a relationship between the ADC values and the intratumoural stroma proportion [32–35]. However, with the exception of the publication by Yamaguchi et al., these studies applied alternative methods than TSR, to express the amount of cellular and stromal components.

Since ADC-values are not fully standardized for this current application, studies have reported variations of ADC values in this setting [17, 20]. It is possible that the currently applied ADC measurements are not the best parameters to evaluate TSR-ADC correlation, which could have been reflected by the wide range in the standard deviation of the ADC measurement as a sign of tumour inhomogeneity (data not shown). Moreover, it could be argued that the ADC_{mean} does not fully reflect the tumour heterogeneity, and histogram analysis is a more accurate approach. This method relies on characterization of the distribution of all voxels within a tumour region, which has been reported to evaluate tumour heterogeneity more thoroughly, in addition to overcoming low representability of ADC_{mean} methods [36,37]. In efforts to explore whether the more strenuous manual tumour delineation of current ADC measurements could be improved, van Heeswijk et al. set out to combine non-precise tumour delineation with histogram analysis in a rectal cancer cohort. Although, they found a good correlation (ICC = 0.75)

Table 3
ADC measurements in LUMC training cohort and VHIO validation cohort

LUMC training cohort										
	Stroma-low (N = 16)			Stroma-high (N = 17)			P-value	Total (N = 33)		
	Mean	Minimum	Maximum	Mean	Minimum	Maximum		Mean	Minimum	Maximum
Single slice										
ADC _{min}	564.9	230.0	1068.0	575.6	115.0	1079.5	0.90	570.4	115.0	1079.5
ADC _{mean}	1033.8	750.0	1391.0	981.1	734.5	1479.0	0.36	1006.7	734.5	1479.0
Whole-volume										
ADC _{min}	588.2	357.0	1068.0	605.5	278.3	1045.5	0.80	597.1	278.3	1068.0
ADC _{mean}	1030.1	782.9	1411.1	1017.2	734.9	1404.0	0.54	1023.5	734.9	1411.1
VHIO validation cohort										
	Stroma-low (N = 37)			Stroma-high (N = 32)			P-value	Total (N = 69)		
	Mean	Minimum	Maximum	Mean	Minimum	Maximum		Mean	Minimum	Maximum
Single slice										
ADC _{min}	366.7	30.8	860.2	346.3	28.9	854.4	0.82	357.2	28.9	860.2
ADC _{mean}	982.6	199.2	1691.8	1042.7	465.1	1707.3	0.59	1010.5	199.2	1707.3
Whole-volume										
ADC _{min}	341.9	19.4	775.8	393.8	28.9	712.6	0.26	366.0	19.4	775.8
ADC _{mean}	1036.9	442.8	1659.8	1076.1	636.2	1429.6	0.21	1055.1	442.8	1659.8

Abbreviations: ADC Apparent diffusion coefficient

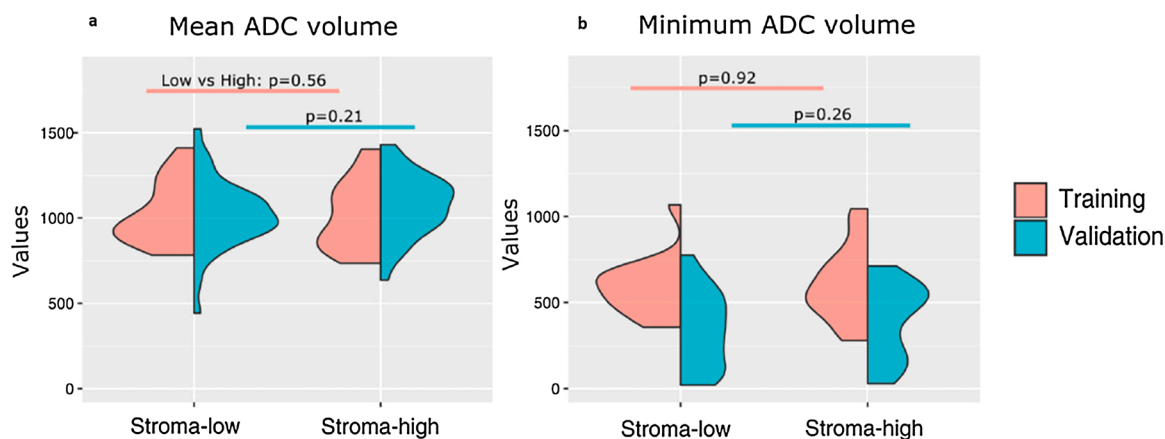


Fig. 3. Violin plot of mean and minimum ADC distribution in LUMC training and VHIO validation cohort.

2a. Mean ADC

2b. Minimum ADC

with the ADC_{mean} of the non-precise delineation, this remained inferior to the agreement results from their previous study, wherein two observers reached an excellent level of agreement when using the precise method ($ICC = 0.98$) [38]. Additionally, the histogram analyses were not able to reproduce previous predictive results of ADC measurements and failed to provide additional prognostic information [39]. Therefore, it remains uncertain whether this approach will truly improve current methods within rectal cancer.

We hypothesized that stroma-low tumours would have lower ADC values, due to the higher cellularity and consequent limited diffusion of free water molecules, but this was not observed within our training cohort nor in the independent validation cohort. A possible explanation could be a relatively small size of the tumours; mean tumour size 23 mm. Perhaps intravoxel incoherent motion (IVIM) imaging based perfusion MRI, a method to quantitatively assess microscopic translational motions (i.e. perfusion of tissue microcirculation and molecular diffusion of water) applied by Yim et al. in breast cancer and by Li et al. in cervical- and breast cancer, could serve as a better imaging entity for correlation to TSR [29–31,40].

We must acknowledge that the TSR scoring was determined on biopsy material and not on resected whole tumour tissue slides, since the latter have been subjected to chemoradiation and therefore do not demonstrate the original tumour morphology. So it must be taken into account that the area with the highest amount of stroma scored on a biopsy, might not necessarily represent the whole tumour content. Remarkably, both cohorts had an almost 50/50 distribution between the TSR categories, which is an uncommon observation since previous colorectal studies typically report a 30/70 ratio for stroma-high and stroma-low tumours, respectively [7,9,10,13,41–43]. However, if a sampling bias would have occurred, an underestimation of the stroma-high tumours would have been more sensible, which was apparent in two studies performed in colon- and oesophageal cancer [44,45]. In these studies, the TSR was determined in diagnostic biopsies and demonstrated the expected lower amount of stroma-high tumours.

Our study had some limitations. First the relatively small sample sizes could have led to the inability to demonstrate a correlation between the TSR and the ADC measurements. However, reproduction of the same results in an independent cohort does seem to support the findings. Secondly, the retrospective nature of the study. Third, we acknowledge that we used the ADC_{mean} values to determine the association with TSR, whereas other studies evaluating the correlation with stroma proportion applied other ADC values (e.g. ADC_{diff}). However, as previously mentioned, ADC measurements are currently not standardized, though the ADC_{mean} is the most widely applied method in published literature which justifies our choice for this method. A final

limitation is the fact that patients from the LUMC cohort were scanned on either a 1.5 T or 3.0 T MRI scanner, respectively 20 (60.6%) and 13 (39.4%) patients. The VHIO cohort was completely performed on a 1.5 T MRI scanner, so strictly only the results of the patients scanned on 1.5 T MRI should be used for correlation. Taking into account the aforementioned limitations, we recommend not to abandon the potential of TSR-ADC correlation right away and encourage validation studies in larger (prospective) cohorts.

5. Conclusion

In conclusion, despite positive reports on the correlation between the intratumoural stroma proportion and ADC values in other solid cancers, we did not find a correlation between the ADC values as derived from MRI-DWI and the TSR in rectal cancer. Reproducibility of ADC values is good.

Credit Author Statement

S.Z.: Conceptualization, Data curation, Investigation, Formal analysis, Writing original draft, review and editing.

B.K., C.M., M.R., R.P.L., A.G.R.: Formal analysis, Writing-review and editing.

G.P.: Formal analysis, Writing-review and editing.

R.D.: Formal analysis of validation cohort.

M.W.: Supervision B.K., C.M., Writing-review and editing.

P.N.: Conceptualization, Writing-review and editing.

H.G., R.T., W.M.: Supervision S.Z., Writing-review and editing.

All authors discussed the results, provided comments and approved the manuscript.

Funding

This study received financial support from “Genootschap Landgoed Keukenhof.” Author R.P.L.’s work is supported by a PCF-Young Investigator Award. The funders had no role in study design, data collection and analysis, decision to publish or preparation of the manuscript.

Declaration of Competing Interest

The authors of this manuscript declare no relationships with any companies, whose products or services may be related to the subject matter of the article.

Acknowledgements

The authors would like to thank prof. dr. Hein Putter for his assistance in the performance of the statistical analyses.

References

- [1] J. Ferlay, E. Steliarova-Foucher, J. Lortet-Tieulent, et al., Cancer incidence and mortality patterns in Europe: estimates for 40 countries in 2012, *Eur J Cancer* 49 (2013) 1374–1403.
- [2] R. Glynn-Jones, L. Wyrwicz, E. Tiret, et al., Rectal cancer: ESMO Clinical Practice Guidelines for diagnosis, treatment and follow-up, *Ann Oncol* 28 (2017) iv22–iv40.
- [3] L. Narunsky, R. Oren, F. Bochner, et al., Imaging aspects of the tumor stroma with therapeutic implications, *Pharmacol Ther* 141 (2014) 192–208.
- [4] D. Hanahan, L.M. Coussens, Accessories to the crime: functions of cells recruited to the tumor microenvironment, *Cancer Cell* 21 (2012) 309–322.
- [5] D. Hanahan, R.A. Weinberg, Hallmarks of cancer: the next generation, *Cell* 144 (2011) 646–674.
- [6] T.J. Dekker, C.J. van de Velde, G.W. van Pelt, et al., Prognostic significance of the tumor-stroma ratio: validation study in node-negative premenopausal breast cancer patients from the EORTC perioperative chemotherapy (POP) trial (10854), *Breast Cancer Res Treat* 139 (2013) 371–379.
- [7] A. Huijbers, R.A. Tollenaar, G.W. v Pelt, et al., The proportion of tumor-stroma as a strong prognosticator for stage II and III colon cancer patients: validation in the VICTOR trial, *Ann Oncol* 24 (2013) 179–185.
- [8] W.E. Mesker, J.M. Junggeburt, K. Szuhai, et al., The carcinoma-stromal ratio of colon carcinoma is an independent factor for survival compared to lymph node status and tumor stage, *Cell Oncol* 29 (2007) 387–398.
- [9] W.E. Mesker, G.J. Liefers, J.M. Junggeburt, et al., Presence of a high amount of stroma and downregulation of SMAD4 predict for worse survival for stage I-II colon cancer patients, *Cell Oncol* 31 (2009) 169–178.
- [10] J.H. Park, C.H. Richards, D.C. McMillan, et al., The relationship between tumour stroma percentage, the tumour microenvironment and survival in patients with primary operable colorectal cancer, *Ann Oncol* 25 (2014) 644–651.
- [11] C. Peng, J. Liu, G. Yang, et al., The tumor-stromal ratio as a strong prognosticator for advanced gastric cancer patients: proposal of a new TSNM staging system, *J Gastroenterol* 53 (2018) 606–617.
- [12] T. Roewe, M. Sobral-Leite, T.J.A. Dekker, et al., The prognostic value of the tumour-stroma ratio in primary operable invasive cancer of the breast: a validation study, *Breast Cancer Res Treat* 166 (2017) 435–445.
- [13] N.P. West, M. Dattani, P. McShane, et al., The proportion of tumour cells is an independent predictor for survival in colorectal cancer patients, *Br J Cancer* 102 (2010) 1519–1523.
- [14] D. Boone, S.A. Taylor, S. Halligan, Diffusion weighted MRI: overview and implications for rectal cancer management, *Colorectal Dis* 15 (2013) 655–661.
- [15] A. Szafer, J. Zhong, J.C. Gore, Theoretical model for water diffusion in tissues, *Magn Reson Med* 33 (1995) 697–712.
- [16] T. Aoyagi, K. Shuto, S. Okazumi, et al., Apparent diffusion coefficient correlation with oesophageal tumour stroma and angiogenesis, *Eur Radiol* 22 (2012) 1172–1177.
- [17] J.W. Choi, D. Lee, S.H. Hyun, et al., Intratumoural heterogeneity measured using FDG PET and MRI is associated with tumour-stroma ratio and clinical outcome in head and neck squamous cell carcinoma, *Clin Radiol* 72 (2017) 482–489.
- [18] E.S. Ko, B.K. Han, R.B. Kim, et al., Apparent diffusion coefficient in estrogen receptor-positive invasive ductal breast carcinoma: correlations with tumor-stroma ratio, *Radiology* 271 (2014) 30–37.
- [19] J.P. Driessen, J. Caldas-Magalhaes, L.M. Janssen, et al., Diffusion-weighted MR imaging in laryngeal and hypopharyngeal carcinoma: association between apparent diffusion coefficient and histologic findings, *Radiology* 272 (2014) 456–463.
- [20] S.J. Hectors, S. Semaan, C. Song, et al., Advanced Diffusion-weighted Imaging Modeling for Prostate Cancer Characterization: Correlation with Quantitative Histopathologic Tumor Tissue Composition-A Hypothesis-generating Study, *Radiology* 286 (2018) 918–928.
- [21] R.N. Matsubayashi, T. Fujii, K. Yasumori, et al., Apparent Diffusion Coefficient in Invasive Ductal Breast Carcinoma: Correlation with Detailed Histologic Features and the Enhancement Ratio on Dynamic Contrast-Enhanced MR Images, *J Oncol* (2010).
- [22] T. Hosonuma, M. Tozaki, N. Ichiba, et al., Clinical usefulness of diffusion-weighted imaging using low and high b-values to detect rectal cancer, *Magn Reson Med Sci* 5 (2006) 173–177.
- [23] D.M. Lambregts, V.C. Cappendijk, M. Maas, et al., Value of MRI and diffusion-weighted MRI for the diagnosis of locally recurrent rectal cancer, *Eur Radiol* 21 (2011) 1250–1258.
- [24] K.M. Bakke, K.H. Hole, S. Dueland, et al., Diffusion-weighted magnetic resonance imaging of rectal cancer: tumour volume and perfusion fraction predict chemoradiotherapy response and survival, *Acta Oncol* 56 (2017) 813–818.
- [25] I.M. Blazic, G.B. Lilic, M.M. Gajic, Quantitative Assessment of Rectal Cancer Response to Neoadjuvant Combined Chemotherapy and Radiation Therapy: Comparison of Three Methods of Positioning Region of Interest for ADC Measurements at Diffusion-weighted MR Imaging, *Radiology* 282 (2017) 615.
- [26] L. Curvo-Semedo, D.M. Lambregts, M. Maas, et al., Diffusion-weighted MRI in rectal cancer: apparent diffusion coefficient as a potential noninvasive marker of tumor aggressiveness, *J Magn Reson Imaging* 35 (2012) 1365–1371.
- [27] G.W. van Pelt, S. Kjaer-Frifeldt, J. van Krieken, et al., Scoring the tumor-stroma ratio in colon cancer: procedure and recommendations, *Virchows Arch* 473 (2018) 405–412.
- [28] D.M. Lambregts, G.L. Beets, M. Maas, et al., Tumour ADC measurements in rectal cancer: effect of ROI methods on ADC values and interobserver variability, *Eur Radiol* 21 (2011) 2567–2574.
- [29] X. Li, P. Wang, D. Li, et al., Intravoxel incoherent motion MR imaging of early cervical carcinoma: correlation between imaging parameters and tumor-stroma ratio, *Eur Radiol* 28 (2018) 1875–1883.
- [30] H. Yim, D.K. Kang, Y.S. Jung, et al., Analysis of kinetic curve and model-based perfusion parameters on dynamic contrast enhanced MRI in breast cancer patients: Correlations with dominant stroma type, *Magn Reson Imaging* 34 (2016) 60–65.
- [31] Y. Li, Z. Wang, F. Chen, et al., Intravoxel incoherent motion diffusion-weighted MRI in patients with breast cancer: Correlation with tumor stroma characteristics, *Eur J Radiol* 120 (2019), 108686.
- [32] H. Bae, S. Yoshida, Y. Matsuoka, et al., Apparent diffusion coefficient value as a biomarker reflecting morphological and biological features of prostate cancer, *Int Urol Nephrol* 46 (2014) 555–561.
- [33] N. Koremezli Keskin, P. Balci, I. Basara Akin, et al., Detection of the differences in the apparent diffusion coefficient values in different histopathological types of malignant breast lesions and comparison of cellular region/ stroma ratio and histopathological results, *Turk J Med Sci* 48 (2018) 817–825.
- [34] D.L. Langer, T.H. van der Kwast, A.J. Evans, et al., Prostate tissue composition and MR measurements: investigating the relationships between ADC, T2, K(trans), v(e), and corresponding histologic features, *Radiology* 255 (2010) 485–494.
- [35] K. Yamaguchi, Y. Hara, I. Kitano, et al., Tumor-stromal ratio (TSR) of invasive breast cancer: correlation with multi-parametric breast MRI findings, *Br J Radiol* (2019), 20181032.
- [36] S.H. Cho, G.C. Kim, Y.J. Jang, et al., Locally advanced rectal cancer: post-chemoradiotherapy ADC histogram analysis for predicting a complete response, *Acta Radiol* 56 (2015) 1042–1050.
- [37] N. Just, Improving tumour heterogeneity MRI assessment with histograms, *Br J Cancer* 111 (2014) 2205–2213.
- [38] M.M. van Heeswijk, D.M. Lambregts, J.J. van Griethuysen, et al., Automated and Semiautomated Segmentation of Rectal Tumor Volumes on Diffusion-Weighted MRI: Can It Replace Manual Volumetry? *Int J Radiat Oncol Biol Phys* 94 (2016) 824–831.
- [39] M.M. van Heeswijk, D.M.J. Lambregts, M. Maas, et al., Measuring the apparent diffusion coefficient in primary rectal tumors: is there a benefit in performing histogram analyses? *Abdom Radiol (NY)* 42 (2017) 1627–1636.
- [40] D. Le Bihan, What can we see with IVIM MRI? *Neuroimage* 187 (2019) 56–67.
- [41] A. Huijbers, G.W. van Pelt, R.S. Kerr, et al., The value of additional bevacizumab in patients with high-risk stroma-high colon cancer. A study within the QUASAR2 trial, an open-label randomized phase 3 trial, *J Surg Oncol* (2018).
- [42] R. Scheer, A. Baidoshvili, S. Zoidze, et al., Tumor-stroma ratio as prognostic factor for survival in rectal adenocarcinoma: A retrospective cohort study, *World J Gastrointest Oncol* 9 (2017) 466–474.
- [43] S.M. Zunder, G.W. van Pelt, H.J. Gelderblom, et al., Predictive potential of tumour-stroma ratio on benefit from adjuvant bevacizumab in high-risk stage II and stage III colon cancer, *Br J Cancer* (2018).
- [44] E.F. Courrech Staal, V.T. Smit, M.L. van Velthuysen, et al., Reproducibility and validation of tumour stroma ratio scoring on oesophageal adenocarcinoma biopsies, *Eur J Cancer* 47 (2011) 375–382.
- [45] T.F. Hansen, S. Kjaer-Frifeldt, J. Lindebjerg, et al., Tumor-stroma ratio predicts recurrence in patients with colon cancer treated with neoadjuvant chemotherapy, *Acta Oncol* 57 (2018) 528–533.