



## TECHNICAL NOTE

# A standardized stepwise approach to minimally invasive ileocolic anastomosis: Tips and tricks for laparoscopic and robotic surgery

Alejandro Solís-Peña<sup>1</sup> | Arturo Cirera<sup>1</sup> | Miquel Kraft Carré<sup>1</sup> |  
Gianluca Pellino<sup>1,2</sup> | Eloy Espín-Basany<sup>1</sup>

<sup>1</sup>Colorectal Surgery, Vall d'Hebron University Hospital, Universitat Autònoma de Barcelona (UAB), Barcelona, Spain

<sup>2</sup>Department of Advanced Medical and Surgical Sciences, Università degli Studi della Campania "Luigi Vanvitelli", Naples, Italy

## Correspondence

Gianluca Pellino, Department of Advanced Medical and Surgical Sciences, Università degli Studi della Campania 'Luigi Vanvitelli', Naples, Italy.  
Email: [gipe1984@gmail.com](mailto:gipe1984@gmail.com); [gianluca.pellino@unicampania.it](mailto:gianluca.pellino@unicampania.it)

Eloy Espín-Basany, Colorectal Surgery, Vall d'Hebron University Hospital, Universitat Autònoma de Barcelona UAB, Barcelona, Spain.  
Email: [eespin@vhebron.net](mailto:eespin@vhebron.net)

## Abstract

**Aim:** Intracorporeal anastomosis has been associated with earlier recovery of postoperative bowel function, shorter length of stay and lower surgical site infection rates. The aim of this work is to describe a step-by-step standardized technique for intracorporeal ileocolic and ileosigmoid anastomosis suitable for laparoscopic and robotic colectomy.

**Method:** Each step of the technique is illustrated using a composite collection of three operative patient videos. Two procedures were performed robotically and one was laparoscopic. Tips are provided to construct a two-layer anastomosis (both posteriorly and anteriorly). The procedures are presented in stepwise fashion, discussing the advantages and feasibility of the technique.

**Results:** The standardized technique described herein was used in three patients for this report, of whom two underwent right colectomy and one subtotal colectomy for cancer. The median operating time was 255 (206–333) min. There were no intraoperative complications. No major postoperative complications or 30-day readmissions occurred. The median length of stay was 4 (3–5) days.

**Conclusion:** The described technique of a two-layer anastomosis can be used with any available minimally invasive approach. It is safe and feasible. Using a standardized approach, the technique can be easily taught and mastered, optimizing operating times and reducing adverse events.

## KEYWORDS

ileocolic anastomosis, intracorporeal anastomosis, laparoscopic approach, robotic approach

## INTRODUCTION

Several studies have demonstrated the advantages of minimally invasive surgery compared with open surgery after an oncological colorectal resection [e.g. fewer surgical site infections (SSI), less use of analgesics, etc.] with equivalent results. By means of these findings, the minimally invasive approach is now considered by many groups to be the standard of care for colorectal cancer [1]. Both laparoscopic

right colectomy and extended right colectomy are well-established procedures for the treatment of right-sided colon neoplasms [2]. As with right colectomy, the laparoscopic approach shows the same advantages in subtotal colectomy [3]. Robotic-assisted procedures seem to have reduced conversion rates in 'difficult cases' and facilitate the procedure by means of increased dexterity and range of motions [4]. Ileocolic anastomoses can be performed using several techniques, for example extracorporeal versus intracorporeal,

This is an open access article under the terms of the [Creative Commons Attribution](https://creativecommons.org/licenses/by/4.0/) License, which permits use, distribution and reproduction in any medium, provided the original work is properly cited.

© 2022 The Authors. *Colorectal Disease* published by John Wiley & Sons Ltd on behalf of Association of Coloproctology of Great Britain and Ireland.

mechanical versus hand-sewn and single- versus double-layered. Intracorporeal anastomosis has potential advantages over extracorporeal, such as reduced traction on the mesentery, full visualization of every step with the reduction of ileum twist or specimen extraction via smaller incisions, with better cosmesis [2,5,6]. Although there are many ways to fashion an intracorporeal anastomosis, some studies have demonstrated that a double-layered anastomosis reduces the clinical impact of anastomotic leaks [7]. Both laparoscopic and robotic intracorporeal anastomosis have been associated with earlier return of bowel function, shorter length of stay, lower morbidity and lower SSI rates [5,8]. Thus, the main indications for this technique are ileocolic and ileosigmoid anastomosis after right, extended right and subtotal colectomies, respectively.

## METHOD

We present our standardized technique of intracorporeal, stapled, ileocolic and ileosigmoid anastomosis reinforced on both sides with a hand-sewn suture, thereby creating a 'double-layered' (both anteriorly and posteriorly) anastomosis. Video S1 (parts 1 and 2) shows a step-by-step technique for performing the anastomosis both with laparoscopy and robotic-assisted surgery. At our hospital we use the DaVinci Xi™ platform (Intuitive Surgical™). Each step is illustrated using a composite collection of three operative patient videos. Two procedures were performed robotically and one was laparoscopic.

### Patient positioning

After the entire dissection has been completed and both the ileum and colon have been sectioned either robotically or laparoscopically,

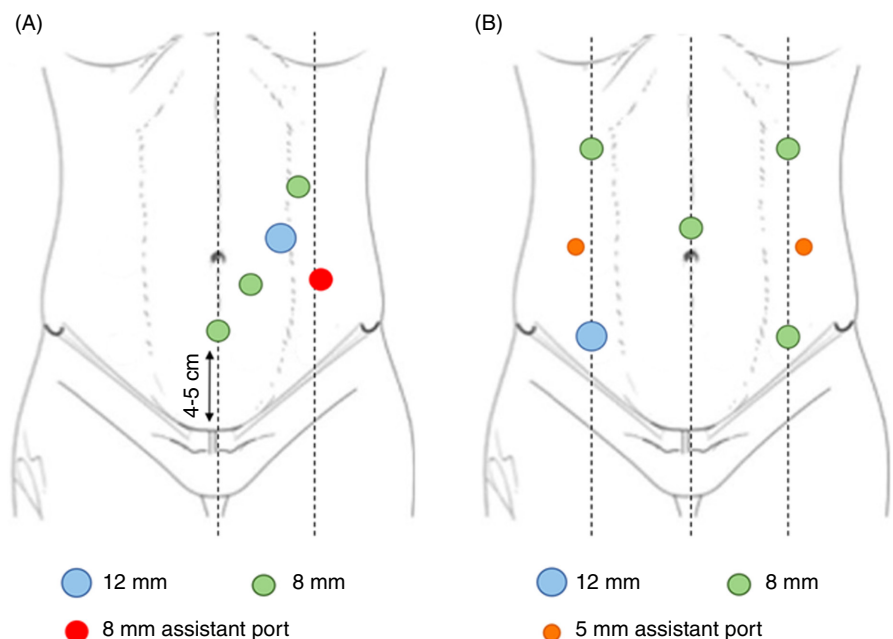
with the patient in a supine position, the lateral tilt is removed (both during right colectomy and subtotal colectomy). During laparoscopic surgery, the operating surgeon stands on the left of the patient, with the assistant surgeon on his/her left side; during robotic surgery, the assistant is on the left of the patient while the operating surgeon sits at the console.

### Port placement

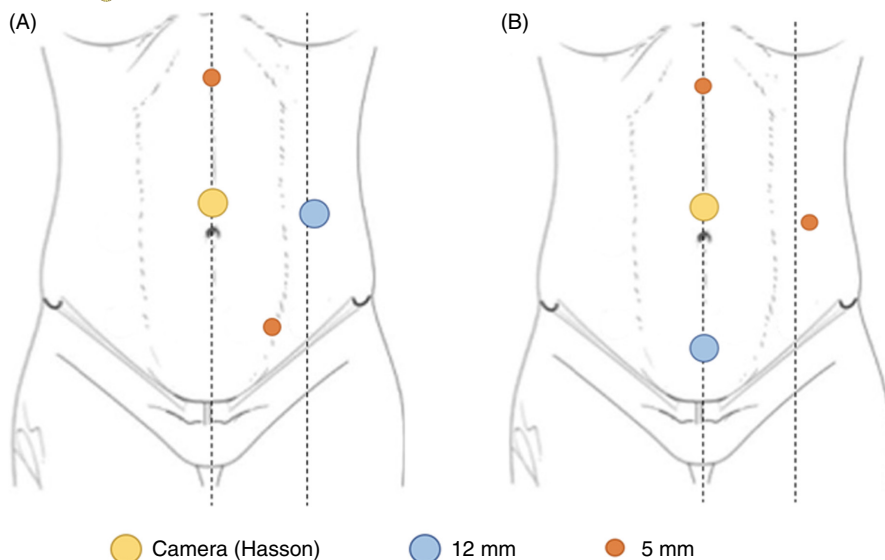
In robotic-assisted right colectomy five trocars are positioned as follows: one 8 mm port is placed in the midline, 4–5 cm above the pubis; then, three robotic trocars are placed cranially between the midline and midclavicular line (two 8 mm ports and a 12 mm port in position 3 or 4). In addition, one 8 mm laparoscopic assistant trocar is placed at the level of the midclavicular left line, between trocars 2 and 3 (Figure 1).

A total of seven trocars are required to perform fully robotic subtotal colectomy. These comprise four 8 mm robotic ports located respectively in both upper quadrants, the lower left quadrant and periumbilical. The 12 mm fifth robotic trocar is located, as shown in the figure, in the right lower quadrant. In addition, two 5 mm laparoscopic assistance trocars are used, located in both flanks (Figure 1B).

In the laparoscopic technique, two different alternatives for trocar placement are suggested. In the first one, a periumbilical Hasson port is placed, through which the camera is inserted. Next, a 12 mm trocar is positioned in the left flank and two 5 mm ports go in the epigastrium and the left lower quadrant, respectively (Figure 2A). Alternatively, the 12 mm trocar can be positioned just above the pubis, so that the 5 mm port would move towards the left flank (Figure 2B).



**FIGURE 1** Trocar placement for robot-assisted right colectomy (A) and for robot-assisted subtotal colectomy (B)



**FIGURE 2** Trocar placement for laparoscopic right colectomy (A, standard technique; B, alternative disposition)

**TABLE 1** Patient characteristics, surgical details, and postoperative outcomes

	Clinical case 1	Clinical case 2	Clinical case 3
Age (years)	74	38	68
Gender	Female	Male	Male
Body mass index (kg/m <sup>2</sup> )	28.3	26.9	27.7
Location of the tumour	Right colon	Right colon	Mid-transverse colon
Signs and symptoms at diagnosis	Asymptomatic	Microcytic anaemia	Asymptomatic
<b>Surgical details</b>			
Type of surgery	Robot-assisted right colectomy	D3 laparoscopic right colectomy	Robot-assisted subtotal colectomy
Duration of surgery (min)	206	255	333
Blood loss (ml)	<100	<100	<100
Intraoperative complications	None	None	None
<b>Outcomes</b>			
Postoperative complications	None	None	Nausea and vomiting
Hospital stay (days)	3	4	5
Pathology	Adenocarcinoma (pT3 pN1a pM0)	Adenocarcinoma (pT3 pN0 pM0)	Adenocarcinoma (pT3 pN0 pM0)

## Docking

The robot is at the right side of the patient at a 90° angle during the right colectomy, and between the legs during subtotal colectomy. The robot arms are aligned with the trocars and docking is performed. Robotic instruments are introduced under direct vision.

## Surgical steps

The anastomosis is started with a running suture of the posterior plane using a barbed thread. Once the posterior component of the anastomosis has been completed, an ileal and a colonic enterotomy are performed with monopolar energy. A side-to-side mechanical anastomosis is fashioned using an Endostapler. Another continuous barbed suture is used to close the defect, starting from the

closest corner to the posterior suture and ending a few centimetres beyond the end of the buttonhole. The standardized technique also includes an anterior reinforcement using a continuous barbed suture.

## COMPARISON WITH OTHER METHODS, ADVANTAGES AND DISADVANTAGES

Compared with other ileocolic anastomotic techniques, our procedure has been standardized to be utilized by all surgeons in our team, including surgeons in training and fellows. Intra- and interoperator variabilities are eliminated, likely reducing postoperative complications related to the anastomosis. The adoption of a homogeneous approach facilitates the learning process for surgical trainees and audit of the skills training process.



The use of the 'double layer' or hand-sewn reinforcement of the anterior and posterior sides of the anastomosis has not been associated with reduced rates of anastomotic leak, but it has reduced the need for reoperation in the case of anastomotic leak, that is, it reduces the clinical impact of an anastomotic leak [7].

With the current technique, the closure of the enterotomy is achieved with a double-layer, full-thickness, running barbed suture. Some studies have demonstrated the feasibility and safety of this type of suture, with similar complication rates of conventional suture closure [9,10]. In addition, in a multicentre case-control study published in 2020 with 1092 patients who underwent right colectomy with ileocolic anastomosis, a significant reduction was found on both anastomotic leak and bleeding with the running suture performed with a barbed suture thread. No differences were seen between laparoscopic and the robotic-assisted approaches [11].

Lastly, intracorporeal anastomosis, compared with the extracorporeal approach, not only has similar rates of anastomotic leak but has also been shown to lower the risk for global, medical and surgical complications, SSI and wound complications, including the rate of incisional hernias, and to shorten the hospital stay [2,12-14].

## RESULTS

We describe data from three different patients diagnosed with nonmetastatic colorectal cancer and who were operated on either by laparoscopy or robotic-assisted surgery: two cases of right colectomy and one case of subtotal colectomy. After the colonic resection, an ileocolic anastomosis following the standardized technique was performed in all cases. Pathology was consistent with colon adenocarcinomas in all patients. In all cases, a Pfannenstiel incision was performed for the specimen extraction because it has a lower incidence of incisional hernia as well as better cosmetic results. Demographic and operative details of the patients are listed in Table 1. No major intra- and postoperative complications were observed, including ones related to the anastomotic status (leak, bleeding or stricture). The median length of hospital stay was 4 days. Detailed surgical and postoperative outcomes are shown in Table 1.

## CONCLUSIONS

The minimally invasive intracorporeal ileocolic anastomosis technique is an effective, feasible and safe procedure. The described technique makes it replicable regardless of the approach used (laparoscopic or robotic) and harmonizes a complex procedure, being particularly suitable for training units or academic hospitals.

## ACKNOWLEDGEMENTS

The authors wish to thank Dr Claudia Alcaraz Soler for the video voice narration. Open Access Funding provided by Universita

degli Studi della Campania Luigi Vanvitelli within the CRUI-CARE Agreement. [Correction added on 18 May 2022, after first online publication : Funding statement has been added.]

## CONFLICT OF INTEREST

The authors declare that they have no conflict of interests.

## AUTHOR CONTRIBUTIONS

ASP, AC, MKC collected data, prepared the video, and drafted the manuscript. GP and EEB critically revised the article. All authors approved the last version that was accepted for publication.

## ETHICAL APPROVAL

This work adhered to the Declaration of Helsinki. All patients provided consent before undergoing the surgical procedure.

## DATA AVAILABILITY STATEMENT

The data that support the findings of this study are available from the corresponding author upon reasonable request.

## ORCID

Alejandro Solís-Peña  <https://orcid.org/0000-0001-5536-9559>

Arturo Cirera  <https://orcid.org/0000-0002-4972-5315>

Miquel Kraft Carré  <https://orcid.org/0000-0002-5642-1694>

Gianluca Pellino  <https://orcid.org/0000-0002-8322-6421>

Eloy Espín-Basany  <https://orcid.org/0000-0002-9139-4548>

## TWITTER

Alejandro Solís-Peña  @AlejandroSolP

Arturo Cirera  @ArturoCirera

Miquel Kraft Carré  @MiquelKraft

Gianluca Pellino  @GianlucaPellino

Eloy Espín-Basany  @eloiespin

## REFERENCES

- Lee SW. Laparoscopic procedures for colon and rectal cancer surgery. *Clin Colon Rectal Surg.* 2009;22(4):218-24. <https://doi.org/10.1055/s-0029-1242461>
- van Oostendorp S, Elfrink A, Borstlap W, Schoonmade L, Sietses C, Meijerink J, et al. Intracorporeal versus extracorporeal anastomosis in right hemicolectomy: a systematic review and meta-analysis. *Surg Endosc.* 2017;31(1):64-77. <https://doi.org/10.1007/s00464-016-4982-y>
- Lorenzon L, La Torre M, Ziparo V, Montebelli F, Mercantini P, Balducci G, et al. Evidence based medicine and surgical approaches for colon cancer: evidences, benefits and limitations of the laparoscopic vs open resection. *World J Gastroenterol.* 2014;20(13):3680-92. <https://doi.org/10.3748/wjg.v20.i13.3680>
- Morelli L, Guadagni S, Di Franco G, Palmeri M, Di Candio G, Mosca F. Da Vinci single site© surgical platform in clinical practice: a systematic review. *Int J Med Robot.* 2016;12(4):724-34. <https://doi.org/10.1002/rcs.1713>
- Allaix ME, Degiuli M, Bonino MA, Arezzo A, Mistrangelo M, Passera R, et al. Intracorporeal or extracorporeal ileocolic anastomosis after laparoscopic right colectomy: a double-blinded randomized controlled trial. *Ann Surg.* 2019;270(5):762-7. <https://doi.org/10.1097/SLA.0000000000003519>

6. Małczak P, Wysocki M, Pisarska-Adamczyk M, Major P, Pędziwiatr M. Bowel function after laparoscopic right hemicolectomy: a randomized controlled trial comparing intracorporeal anastomosis and extracorporeal anastomosis. *Surg Endosc*. 2021. <https://doi.org/10.1007/s00464-021-08854-8>
7. Espin E, Vallribera F, Kreisler E, Biondo S. Clinical impact of leakage in patients with handsewn vs stapled anastomosis after right hemicolectomy: a retrospective study. *Colorectal Dis*. 2020;22(10):1286–92. <https://doi.org/10.1111/codi.15098>
8. Guadagni S, Palmeri M, Bianchini M, Gianardi D, Furbetta N, Minichilli F, et al. Ileo-colic intra-corporeal anastomosis during robotic right colectomy: a systematic literature review and meta-analysis of different techniques. *Int J Colorectal Dis*. 2021;36(6):1097–110. <https://doi.org/10.1007/s00384-021-03850-9>
9. Feroci F, Giani I, Baraghini M, Romoli L, Zalla T, Quattromani R, et al. Barbed versus traditional suture for enterotomy closure after laparoscopic right colectomy with intracorporeal mechanical anastomosis: a case-control study. *Updates Surg*. 2018;70(4):433–9. <https://doi.org/10.1007/s13304-017-0502-4>
10. Ferrer-Márquez M, Torres-Fernández R, Rubio-Gil F, Belda-Lozano R, Moya-Forcén P, Benavides Buleje JA, et al. Use of barbed suture for the closure of enterocolotomy after laparoscopic right hemicolectomy with intracorporeal anastomosis. A prospective descriptive study. *Cir Esp (Engl Ed)*. 2020;98(3):136–42. <https://doi.org/10.1016/j.ciresp.2019.10.002> English, Spanish. Epub 2019 Dec 6.
11. Milone M, Elmore U, Allaix ME, Bianchi PP, Biondi A, Boni L, et al. Fashioning enterotomy closure after totally laparoscopic ileocolic anastomosis for right colon cancer: a multicenter experience. *Surg Endosc*. 2020;34(2):557–63. <https://doi.org/10.1007/s00464-019-06796-w>
12. Vallribera F, Kraft M, Pera M, Vidal L, Espín-Basany E. Outcomes of intra- versus extra-corporeal ileocolic anastomosis after minimally invasive right colectomy for cancer: an observational study. *J Clin Med*. 2021;10(2):307. <https://doi.org/10.3390/jcm10020307>
13. Lujan HJ, Plasencia G, Rivera BX, Molano A, Fagenson A, Jane LA, et al. Advantages of robotic right colectomy with intracorporeal anastomosis. *Surg Laparosc Endosc Percutan Tech*. 2018;28(1):36–41. <https://doi.org/10.1097/SLE.0000000000000384>
14. Emile SH, Elfeki H, Shalaby M, Sakr A, Bassuni M, Christensen P, et al. Intracorporeal versus extracorporeal anastomosis in minimally invasive right colectomy: an updated systematic review and meta-analysis. *Tech Coloproctol*. 2019;23(11):1023–35. <https://doi.org/10.1007/s10151-019-02079-7>

## SUPPORTING INFORMATION

Additional supporting information may be found in the online version of the article at the publisher's website.

**How to cite this article:** Solís-Peña A, Cirera A, Kraft Carré M, Pellino G, Espín-Basany E. A standardized stepwise approach to minimally invasive ileocolic anastomosis: Tips and tricks for laparoscopic and robotic surgery. *Colorectal Dis*. 2022;24:1238–1242. <https://doi.org/10.1111/codi.16159>